

Case Report

Symptomatic Lumbar Epidural Synovial Cyst: A Case Report

Gyawali D, Sharma MR, Pradhananga A, Shrestha Piya E

Chirayu National Hospital and Medical Institute, Basundhara, Kathmandu, Nepal

Correspondence to: Prof. Mohan R. Sharma, MS, Chirayu Hospital, Basundhara, Kathmandu, Nepal

Email: mohanrajsharma@gmail.com

Abstract

The authors report on a 70-year-old woman with a synovial cyst compressing the thecal sac at L₄₋₅ level. The patient presented with severe, unremitting back pain radiating to both buttocks of three months' duration. Her general physical and neurological examination was largely normal. The patient underwent magnetic resonance imaging which revealed a right sided extradural cystic lesion at L₄₋₅ level with a significant thecal compression. Given the imaging evidence of space occupying lesion and severe symptoms refractory to analgesics and physical therapy, surgery was performed. She underwent bilateral L₅ laminectomy and complete excision of the cystic lesion. The histopathology was compatible with the diagnosis of synovial cyst. She had uneventful postoperative period and discharged home pain free on postoperative day 4. This case highlights the importance of investigating an underlying disease process in patients who present with significant back pain and offering the tailored treatment to individual patients with spinal synovial cysts.

Introduction

Epidural cystic lesions causing symptomatic thecal sac compression is a relatively rare phenomenon in neurosurgical practice.^(1,2,3) Even rarer is the synovial cyst arising from the adjacent facet joint protruding into the spinal canal causing symptomatic compression.^(2,3) The presentation of this disease is nonspecific. Magnetic resonance imaging (MRI) is the investigation of choice which narrows down the differential diagnosis.^(4,5) Once the diagnosis is made, treatment options vary ranging from watchful waiting to surgical excision.^(6,7) Surgical excision serves the dual purpose of relief of symptoms and histological verification. We recently came across a 70-year old lady with a synovial cyst in the lumbar region who was managed operatively at our institute. We report this case in detail in addition to reviewing the pertinent literature.

Case Description

History

This 70-year-old lady presented to us with a 3-month history of severe unremitting low back pain which

radiated to both buttocks and back of the thigh. The pain used to get aggravated by walking. There was no prior history of trauma. There were no sensory symptoms and her bowel and bladder was normal.

Examination

Her general physical examination was normal. On neurological examination, she had normal motor and sensory functions. There was slight localized tenderness on the right paraspinal area at L₄ and L₅ levels.

Imaging

Her plain x-ray of the lumbosacral spine was normal. A lumbosacral MRI was performed which revealed a right sided extradural cystic lesion juxtaposed to L₄₋₅ facet joint (Figure 1). The lesion was significantly compressing the thecal sac.

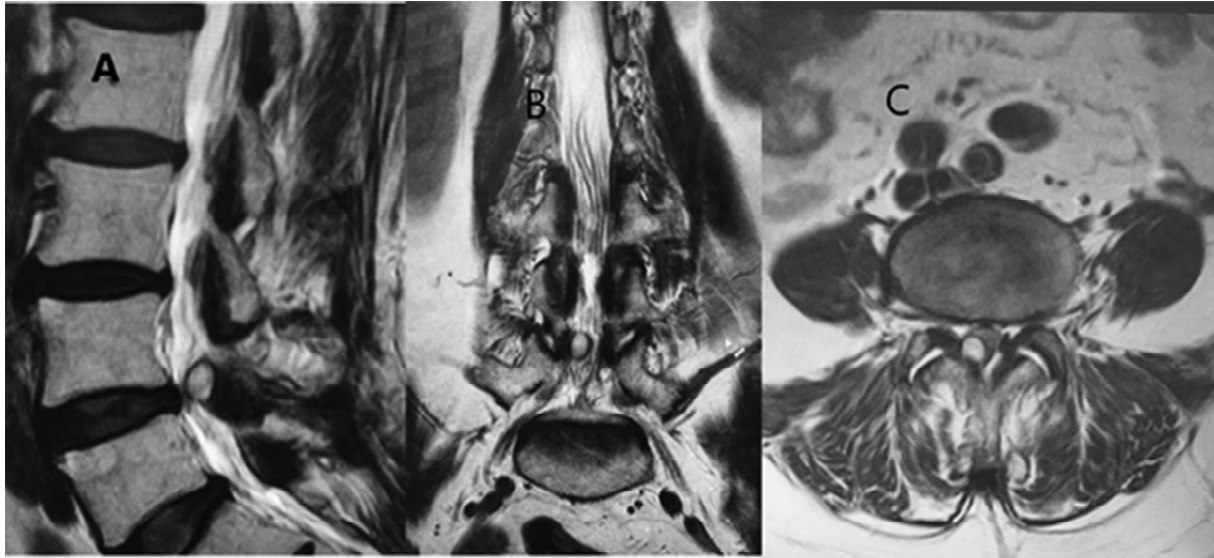


Figure 1. MRI of the lumbosacral spine T2 weighted images, A) Sagittal, B) Coronal and C) Axial views showing the characteristic cystic lesion (arrows) at L₄₋₅ disc level causing significant thecal sac compression.

Hospital Course

Due to the uncertainty of diagnosis and severity of symptoms (she had already received analgesics and physical therapy elsewhere with little or no relief), surgery was offered. She underwent bilateral L₅ laminectomy and complete excision of the cystic lesion. Intraoperatively a well-demarcated extradural cyst was found compressing the dural sac markedly. The cystic lesion had attached firmly to the right L₄₋₅ facet joint. The cyst contained thin clear fluid with some flecks of calcification but no signs of hemorrhage. The histopathological examination showed fibrocollagenous cyst wall without epithelial lining and extensive calcification with foci of myxoid material inside. Though true synovial cysts have epithelial lining, our patient lacked it. So, this fell in the diagnosis of spinal synovial cyst, a continuum between true synovial and ganglion cyst (Figure 2).⁸ She had uneventful postoperative period and discharged home pain free on postoperative day 4. On follow up visit at 3 months, she was symptom free and neurologically intact.

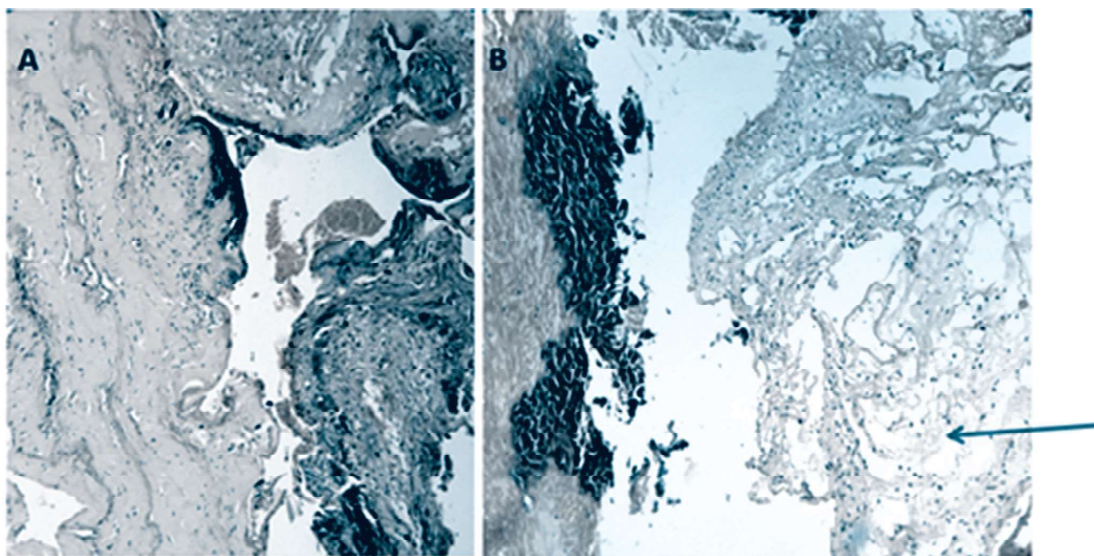


Figure 2. Photomicrograph showing A) Fibrocollagenous cyst wall without epithelial lining and extensive calcification, and B) Cyst cavity containing myxoid material (arrow).

Discussion

There are various lesions in the epidural space in the spine causing thecal or nerve root compression.^(1, 2,3) The commonest are spinal tumors and disc pathologies. Rare are the cystic lesions in this location.^(4,7,9) Various cystic lesions described are ganglion, synovial, discal and paracystic.⁽²⁾ Synovial cysts are uncommon causes of spinal compression.⁽¹⁾

Synovial cysts were first described by Baker in 1885 as cystic dilatations of synovial sheaths adjacent to a joint. They occur throughout the body. Lumbar synovial cysts directly arise from facet joints and extrude into the spinal canal due to chronic degenerative process.^(1,6) The majority of these cysts in the lumbar spine occur at the L4–L5 level which is the site of maximum mobility.^(1,5) There is slight female predilection for the disease and often encountered after the 6th decade of life.⁽¹⁾ To date debate continues regarding its origin, cause, pathology and the best modality of treatment.

The exact etiology of synovial cysts in the spine is unknown. Underlying spinal instability, facet joint arthropathy and degenerative spondylolisthesis have been found to have a strong association for worsening symptoms and formation of spinal cysts.^(1,2,3) Histopathologically synovial cysts are internally lined with cuboid or pseudostratified columnar epithelium and filled with clear or straw color fluid.⁽¹⁾ Rarely these cysts can bleed into surrounding soft tissues and or spinal canal causing acute spinal compression.

Symptoms and signs are directly related to the size and the rapidity of the epidural growth of these cysts into the spinal canal. The majority are asymptomatic and detected on routine imaging. Common presenting features are low back and radicular pain with a varying degree of neurological deficits.^(4,5,6)

For the diagnosis, plain radiographs are of little diagnostic importance. Though computed tomography (CT) scan sometimes suggests the pathology, MRI is the investigation of choice.⁽⁵⁾ MRI demonstrates the nature and volume of the cystic lesion and its relationship to the adjacent bony and neural structures. Typical MRI characteristics include a well circumscribed, smooth, extradural cyst adjacent to the facet joint. The proteinaceous content of the cyst means that a greater signal intensity than the surrounding CSF is expected on both T1 and T2 weighted images.⁽⁵⁾

There is controversy regarding the appropriate treatment of these lesions.^(1,2,4,6,7,8,9) The best treatment option for each particular individual should be based upon the severity of symptoms, radiological findings and other co-morbidities. The indications for surgery are confirmation of diagnosis and relief of symptoms. Though simple aspiration of the cyst has also been advocated, it has got high recurrence rate.⁽¹⁰⁾

Conclusion

Several types of cystic lesions causing various degrees of neural compression are found in the lumbar spine. The lumbar synovial cysts must be considered as possible causes for spinal or radicular symptoms especial in an elderly female.

References

1. Khan AM, Giradi F. Spinal lumbar synovial cysts. Diagnosis and management challenge. *Eur Spine J*. 2006 Aug; 15(8): 1176–1182.
2. Santos FGPL, Souza RA, Brotto MPD, Suguita FM, Amaral DT, Amaral LLF. Epidural cystic masses associated with interspinous bursitis, synovial and discal cysts. *Radiol Bras*. 2009; 42(2):131–135.
3. Pindrik J, Macki M, Bydon M, Maleki Z, Bydon A. Midline synovial and ganglion cysts causing neurogenic claudication. *World J Clin Cases*. 2013 Dec 16; 1(9): 285–289.
4. Boody BS, Savage JW. Evaluation and Treatment of Lumbar Facet Cysts. *J Am Acad Orthop Surg*. 2016 Dec; 24(12):829-842.
5. Khalatbari K, Ansari H. MRI of degenerative cysts of the lumbar spine. *Clin Radiol*. 2008 Mar;63(3):322-8
6. Denis DR, Hirt D, Shah S, Lu DC, Holly LT. Minimally invasive surgery for lumbar synovial cysts with coexisting degenerative spondylolisthesis. *Int J Spine Surg*. 2016; 10: 37.
7. Lyons MK, Atkinson JL, Wharen RE, Deen HG, Zimmerman RS, Lemens SM. Surgical evaluation and management of lumbar synovial cysts: the Mayo Clinic experience. *J Neurosurg*. 2000 Jul;93(1 Suppl):53-7
8. Acharya R, Patwardhan RV, Smith Dr, Willis, BK, Fowler M, Nanda, A. Intraspinal synovial cyst: A retrospective study. *Neurol India*. 2006, 54:38-41
9. Freidberg SR, Fellows T, Thomas CB, Mancall AC. Experience with symptomatic spinal epidural cysts. *Neurosurgery*. 1994 Jun;34(6):989-93
10. Epstein NE, Baisden J. The diagnosis and management of synovial cysts: Efficacy of surgery versus cyst aspiration. *Surg Neurol Int*. 2012; 3(Suppl 3): S157–S166.