

Orbito-Cranial Injury Caused by Penetrating Wooden Piece

Gautam P, Shah DN

Department of ophthalmology BP Koirala lions centre for ophthalmic studies, Institute of Medicine, Maharajgunj Campus

Corresponding Author: Dr. Pragati Gautam, Department of ophthalmology BPKoirala lions centre for ophthalmic studies, Institute of Medicine, Maharajgunj Campus

Email: pragatigautam@hotmail.com

Abstract

We present the case of a 35-year-old man with history of fall 2 days back and an upperlid laceration with foreign body seen in the wound with a new onset of seizure disorder that was found to harbor an intra-parenchymal foreign body related to orbital trauma. Imaging revealed a pneumo-cephalus in the extra-axial space over right frontal lobe anterior pole with focal laceration in basal area of frontal lobe with an obliquely oriented fat/ air attenuating foreign body lodged in the basal area of frontal lobe extending from roof of orbit medially with foreign body indenting the right globe inferiorly.

Introduction

Penetrating wounds to the orbit constitute 30-50% of all traumatic eye injuries. Injury by orbito-cranial foreign bodies mostly presents dramatically but sometimes may be subtle and occult. Low suspicion for intracranial extension leads to delay in diagnosis and may result in life-threatening intracranial complications^{2,3}. The complication rate is higher in orbito-cranial injuries with a mortality rate of approximately 12%; twice the rate for penetrating cranial injury not affecting the orbit⁴. The roof of the orbit provides one of the easiest entry routes for a foreign body into the brain as it is relatively thin in this location. Intra-orbital foreign bodies are usually diagnosed with ease in the presence of obvious penetrating injuries⁵.

A coordinated team approach between an ophthalmologist and neurosurgeon is essential for managing these injuries.⁶

Case report

We report an unusual case of penetrating orbito-cranial injury in an adult male (35 years) by a wooden piece with no mortality but had cerebrospinal fluid (CSF) leak as well as exposure keratopathy in the involved eye. We removed the foreign body through a craniotomy rather than the laceration site even though, this was invasive way to extract the foreign body, as the foreign body was big.

The 35 years old male patient presented to us on emergency with alleged history of fall over a piece of wood which

penetrated to the right eye from medial side. Following which patient had severe pain and was unable to close the right eye. On physical examination, an entry wound was noted at the right upperlid at medial one third with foreign body hooking the lid pointing towards the roof of orbit and pressing on the globe. Visual acuity was difficult to evaluate exactly because of pain, it was better than perception of light (PL). His globe motility was restricted medially and superiorly. He was unable to close right eye (RE). He had evidence of exposure keratopathy RE. He was in pain and discomfort and detail examination was not possible. He had CSF leak. His GCS scale was 15/15 and he was incoherent at times. He also had 2 episodes of seizures. He was started on ceftriaxone, vancomycin and metronidazole intravenous (IV) along with IV phenytoin and acetazolamide oral.

CT revealed a well defined 3.5x1.3x1 cm obliquely oriented fat/ air attenuating foreign body (FB) lodged in extra-conal space in upper quadrant of right orbit, with its posterior end extending through the bony defects in the roof of right orbit and right frontal sinus and extending to cranial cavity in the basal area of anterior cranial fossa on right side with 10 mm long segment of FB seen in cranial cavity in extra-axial space in right frontal lobe. FB was indenting upper wall of eyeball and right superior rectus muscle inferiorly. With neurosurgical consultation patient was taken for emergency operation theatre (OT) after CT scan and other

investigation needful for surgery under general anesthesia. Neurosurgical team did right frontotemporoparietal Craniotomy with foreign body removal with Duroplasty. The wooden foreign body was 5x4x1 cm size on right frontal lobe extending from upper margin of right upper eyelid from medial side of orbit. The breach in dura was 3x2 cm and there was frontal lobe contusion. After foreign body was taken out we, the ophthalmological team explored the wound in upper eyelid. There was full thickness laceration of upper eyelid from where the FB had penetrated the orbit at medial 1/3 with pressure necrosis and tissue loss at that site as well as at the site of bulbar conjunctiva where the wooden piece had pressed on the globe. The globe was intact. The right cornea had features of exposure keratopathy as he presented on 3rd day of trauma and was taken for Operation on 5th day of trauma. The full thickness laceration of upper eyelid was closed in 2 layers with 6-0 vicryal. Skin was closed with 5-0 silk. And debridement of necrotic tissue was done. Intravenous antibiotic treatment was continued. Postoperative recovery was uneventful. We also did temporary tarsorrhaphy on 2nd post operative day (POD) as there was persisting epithelial defect in the centre of cornea. Patient was discharged on 7th POD with 2 more weeks of oral antibiotics, at that time his vision in right eye was 1/60. He had no neurological deficit at the time of discharge. He followed up after 2 weeks at that time his vision was 5/60 in right eye. The cornea was hazy with diffuse macular corneal opacity. Pupil was round regular reacting to light briskly. Media was hazy but fundus was visible. He also visited Neurosurgical OPD.

Discussion

The orbit provides access to the cranial cavity, making it vulnerable to penetrating trauma, which can involve the meninges and central nervous system. The most common routes by which foreign bodies penetrate intra-cranially are through the orbital roof. The most common route of entry is the superior orbital roof². Penetrating orbital trauma is common, and clinical evidence of deep injury may be subtle; the injury may appear deceptively superficial. If wood has a sharp end and is elongated it can penetrate deep into the orbit and the intracranial cavity through a small entry wound⁵. The resistance of the sclera and the displacement of the globe often protect the eye from perforation⁹. Orbital abscess formation in the setting of a retained foreign body after penetrating orbital trauma has been well documented. Serious complications of a retained piece of wood may occur days, months or even years after initial trauma¹⁰.

Wood, with its porous consistency and organic nature, provides a good medium for microbial agents¹¹. Wood

is the most common organic material retrieved from the orbit¹². Unlike small foreign bodies, which are generally located completely within the orbit, large impacted objects in the orbital region cause severe visual impact and require specialized care within as short a period of time as possible¹³.

Cultures of the wound and foreign bodies are recommended at the time of retrieval and we also did that. However, on culture no organism was isolated. This is likely due to the use of antibiotics prior to surgical intervention.

Detection of intra-orbital wooden foreign bodies is important, because severe complications secondary to infection can occur. The risk for late complications increases with organic wooden foreign objects, which can harbor bacteria and fragment during removal. Imaging in the acute setting of suspected penetrating orbital trauma is essential. Plain radiography is usually the first additional exam to be requested due to its low cost and easy access. This imaging exam may be useful in identifying and locating intraorbital foreign bodies, with detection rates of 69 to 90% for metallic foreign bodies and 71 to 77% for glass; however, the detection rate for organic material, such as wood, is low (0 to 15%).¹⁴ Wood is virtually undetectable on routine x-ray film since its radio-density is very similar to that of the soft tissue¹⁵. The detection of an intracranial wooden object by CT scan is also difficult. On CT, wood has been described as low attenuating or high attenuating, depending on the degree of air or other substances trapped within its cellulose matrix¹⁶. It can mimic air within the orbit¹⁷. In our case, the intra-orbital wooden foreign body mimicked air in attenuation on CT images.

Penetrating orbital trauma is common, and clinical evidence of deep injury may be subtle; the injury may appear deceptively superficial. In certain cases of orbital penetrating injury, the foreign body might be missed and go undiagnosed. In such cases, eyelid laceration is sutured without further investigation¹⁰. This delayed diagnosis of the penetrating foreign body is usually associated with more complications, such as orbital cellulitis, cerebral abscess, meningitis, and even delayed neurological deterioration related to slowly expanding intracranial hematoma². However in our case the wooden piece end was seen at the anterior wound and prompt removal with neurosurgical team was carried out.

Our patient also had new onset seizure. New-onset seizures are a typical manifestation of both recent and remote penetrating trauma¹⁸. Mortality has been reported to be high in old literatures due to infections and lack of optimal antimicrobial therapy in setting of transorbital injuries with foreign body³. However in our case the preoperative and

postoperative period was uneventful except for new onset seizure and exposure keratopathy in the involved eye. In study done by Miller et al the survival of patients with intracranial wooden foreign body was only 38% without surgery but improved to 90% with combination of surgery and appropriate antibiotics.¹⁹

Conclusion

In general, the overall outcome of this type of injury is dependent on the degree and types of damage caused by the foreign body penetration. However, early recognition would prevent complications that can be life threatening.

Acknowledgement

Neurosurgical department of institute of medicine and Dr. Anica Shah, Dr. Monika karmacharya

Figure 1: Showing Foreign body on medial part of orbit indenting globe and displacing globe inferiorly

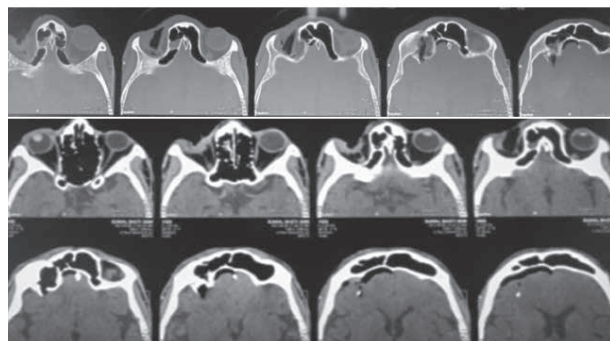
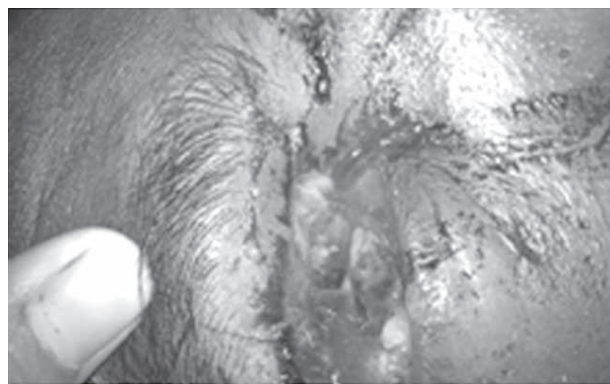

Figure 2:CT Scan-Axial images: showing air attenuating foreign body in right orbit extending upto frontal lobe

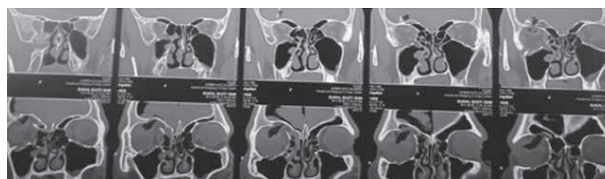


Figure 3: CT scan coronal viewing showing air attenuating foreign body right orbit extending though superomedial orbit to brain

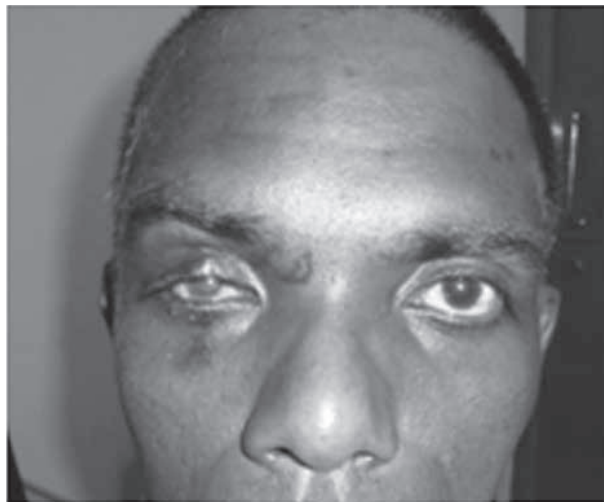

Figure 4: showing patient after undergoing craniotomy with removal of foreign body.

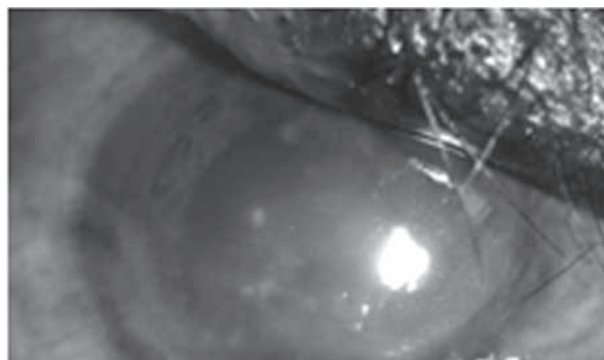


Figure 5: showing right eye with diffuse corneal opacity more marked inferiorly, evidence of exposure keratopathy

References:

1. Ildan F, Bagdatoglu H, Boyar B, Doganay M, Cetinalp E, Karadayi A: The non-surgical management of a penetrating orbitocranial injury reaching the brain stem. *J Trauma* 1994; 36: 116-118
2. Turbin RE, Maxwell DN, Langer PD, Frohman LP, Hubbi B, Wolansky L, et al. Patterns of transorbital intracranial injury: A review and comparison of occult and non-occult cases. *SurvOphthalmol.* 2006; 51:449–60.
3. Bursick DM, Selker RG. Intracranial pencil injuries. *Surg Neurol.* 1981; 16:427–31.
4. Oguz M, Aksungur EH, Atilla E, Mehmet A, Sureyya K, Ildan F: Orbitocranial penetration of a pencil. Extraction under CT control. *Eur J Rad* 1993, 17: 85-87
5. Mutlukan E, Fleck BW, Cullen JC, Whittle IR. Case of penetrating orbitocranial injury caused by wood. *Br J Ophthalmol* 1991; 75: 374-376
6. Fezza J, Wesley R. The importance of CT scans in planning the removal of orbital-frontal lobe foreign bodies. *OphthalmPlastReconstr Surg.* 1999; 15:366–8.
7. Santos TS, Melo AR, et al. Impacted foreign bodies in orbital region: review of nine cases *Arq Bras Oftalmol* . 2010;73(5):438-42
8. Bard LA, Jarret WH. Intracranial complications of penetrating orbital injuries. *Arch Ophthalmol* 1961;71:332–343
9. Hansen JE, Gudeman SK, Holgate RC, Saunders SA. Penetrating intracranial wounds: clinical implications of computerised tomography. *J Neurosurg.* 1988; 68:752–756
10. Uchino A, Kato A, Takase Y, Kudo S: Intraorbital wooden and bamboo foreign bodies: CT. *Neuroradiology* 1997; 39:213-215.
11. Zenter J, Hassler W, Petersen D. A wooden foreign body penetrating the superior orbital fissure. *Neurochirurgia* 1991;34:188–190
12. Orcutt JC: Orbital foreign bodies. In Linberg JV (ed): *Oculoplastic and Orbital Emergencies.* Norwalk, Conn.: Appleton & Lange, 1990:183–197
13. Yago K, Suzuki M, Sasaki S, Nakamura Y. Wooden foreign body in the orbit. *Jpn J ClinOphthalmol.* 1990; 44:439-41
14. Bray LC, Griffiths PG. The value of plain radiography in suspected intraocular foreign body. *Eye (Lond).* 1991;5(Pt 6):751-4.
15. Potapov AA, Yelochiyan SA, Tcherekaev VA, Kornienko VN, Arutyunow NV, Kravtchuk AD, Shahinian GG, Likhtermann LB, Serova NK, Eroptkin SV: Removal of a cranioorbital foreign body by a supraorbital pterior approach. *J Craniofacial Surg* 1996; 7(3): 224-227
16. Glatt HJ, Custer PL, Barrett L, Sartor K. Magnetic resonance imaging and computed tomography in a model of wooden foreign bodies in the orbit. *OphthalmPlastReconstrSurg* 1990; 6:108–114
17. Roberts CF, Leehey PJ III. Intraorbital wood foreign body mimicking air at CT. *Radiology* 1992;185:507–5
18. Annegers JF, Hauser WA, Coan SP, Rocca WA. A populationbased study of seizures after traumatic brain injuries. *N Engl J Med* 1998; 338:20–24
19. Miller CF, Brodkey JS., Colombi BJ. The dangers of intracranial wood. *SurgNEurol* 1997; (7)95-103