

Case Report

Xanthogranulomatous appendicitis: A case report

Thapa R¹, Gurung P¹, Kafle N¹, Pradhanang S¹, Lakhey M¹, Singh DR²¹Department of Pathology, Kathmandu Medical College Teaching Hospital, ²Department of Surgery, Kathmandu Medical College Teaching Hospital, Sinamangal, Kathmandu**Correspondence to:** Dr Rupendra Thapa**E-mail:** rup432@gmail.com**Abstract**

Xanthogranulomatous inflammation is a well described inflammatory condition which can involve any organ but is commonly seen in the gallbladder and kidney. Xanthogranulomatous inflammation involving the appendix is rare with very few cases reported in the literature. Here we report a case of 19 years old girl with xanthogranulomatous appendicitis who underwent interval appendicectomy. Histopathology revealed the presence of predominance of foamy histiocytes admixed with lymphocytes and plasma cells.

Introduction

Xanthogranulomatous inflammation is a well - known form of chronic inflammation involving various organs and characterized histologically by presence of increased number of foamy histiocytes admixed with lymphocytes and plasma cells. It was first reported in the kidney by Osterlind in 1944.¹ The involvement of vermiform appendix by xanthogranulomatous inflammation is a rare phenomenon. It is also regarded as an unusual healing pattern of appendicitis.² We are reporting this case in view of rare occurrence of the disease in the appendix. To the best of our knowledge this is the first reported case of xanthogranulomatous appendicitis from Nepal.

Case report

A 19 years old female developed acute pain in the right iliac fossa and presented to the surgical outpatient department. On clinical examination she was found to have tenderness in the McBurney's point along with rebound tenderness. Her routine blood test revealed neutrophilic leukocytosis. USG (ultrasonogram) abdomen was inconclusive. She was managed symptomatically and the pain subsided. Interval appendicectomy was planned. After six weeks she underwent interval appendicectomy. The specimen was sent to the department of pathology, Kathmandu Medical College Teaching Hospital for histopathological examination.

On gross examination, the appendix measured 6.5x1.5 cm in size. Outer surface appeared congested and

dull. Cut surface showed focal yellowish discoloration of the mucosa. The lumen was patent. (fig. 1)

Hematoxylin and Eosin (H & E) stained sections showed focal ulceration of mucosa, collections of histiocytes with abundant granular eosinophilic cytoplasm, occasional foreign body type multinucleated giant cells admixed with variable amounts of lymphocytes, plasma cells and occasional eosinophils. Lymphoid follicles with germinal centre cells were also seen in the submucosa. (fig. 2 and fig. 3)

Based on the histopathological findings a diagnosis of xanthogranulomatous appendicitis was made.

Discussion

Xanthogranulomatous inflammation is a well- defined form of chronic inflammation which has been described in various organs, most notably in the kidney and gallbladder.^{3,4,5} Xanthogranulomatous inflammation of the appendix is rare.^{6,7,8} On the basis of reported series XA occurs in adults with a mean age of 47.9 year (83%, 21-78 years). It is still rare in paediatric age group. Most of the patients present with right lower quadrant abdominal pain although the duration of pain varies from hours to months. CT scan is the most common imaging method used to detect appendicular mass, however consistent radiological features of XA could not be validated. The exact etiology remains uncertain but the hypothesis or theoretical mechanisms leading to xanthogranulomatous inflammation include defective lipid transport, immunologic disturbance, and infection by low – virulence organisms.³ Cozzutto and Carbone

noted that xanthogranulomatous inflammation is usually seen secondary to inflammation, hemorrhage, and necrosis.⁷

In a study of appendicectomies over a period of four years done by Guo and Greenson, xanthogranulomatous inflammation was seen in 8 out of 22 (36.4%) cases of interval appendicectomies, while no such findings were seen in emergency appendicectomies. They concluded that delayed or interval appendectomy specimens often have a characteristic inflammatory pattern that includes granulomas, xanthogranulomatous inflammation, mural fibrosis/thickening, transmural chronic inflammation with lymphoid aggregates, and mucosal distortion.⁹

Likewise, Mazziotti et al. reported granulomatous appendicitis in interval appendectomy specimens (3 of 17 cases).¹⁰

Patient with ruptured acute appendicitis are often treated with antibiotic therapy and drainage followed by delayed or interval appendectomy. The observation of xanthogranulomatous inflammation in interval appendectomy specimen postulates that interval appendectomy may lead to xanthogranulomatous inflammation. Xanthogranulomatous appendicitis in an acute (non-interval) phase appendicectomies is rare although known.

Other lesions with granulomatous inflammation and foam cells can come in the differential diagnosis, such as Crohn's disease and malakoplakia. The absence of transmural involvement by granulomas and Michaelis-Gutmann bodies ruled out Crohn's disease and malakoplakia respectively in our case. Xanthogranulomatous appendicitis masquerades as malignancy due to presence of diffuse inflammatory and fibrotic changes.¹¹

In a case report of Chung et al. a 39 year man presented with fever, right lower abdominal pain and hard lump. Right hemicolectomy was done in suspicion of malignancy but the final histopathological report suggested xanthogranulomatous appendicitis.¹²

Due to clinical and radiological resemblance of these lesions to neoplastic process, excision and subsequent histopathological examination is mandatory.

Conclusion

Xanthogranulomatous appendicitis is a rare clinical entity. It can be encountered in cases of acute but more often in interval appendicectomies. Clinical, radiologic and endoscopic findings are insufficient for a preoperative diagnosis. Clinical and radiologic resemblance to

neoplastic process warrants excision. Histopathologic examination clinches the final diagnosis.

Conflict of interest: None declared

References

1. Osterlind S. Uber pyelonephritis xanthomatosa. Acta Chir. Scand. 1994; 90: 369-76.
2. Carr NJ, Montgomery E. Patterns of healing in the appendix. The morphologic changes in resolving primary acute appendicitis and a comparison with Crohn's disease. Int J Surg Pathol 1994; 2:23-30.
3. Antonakopoulos GN, Chapple CR, Newman J, et al. Xanthogranulomatous pyelonephritis: a reappraisal and immunohistochemical study. Arch Pathol Lab Med. 1988; 112:275-81.
4. Benbow EW. Xanthogranulomatous cholecystitis. Br J Surg. 1990; 77:255-6.
5. Franco V, Aragona F, Genova G, et al. Xanthogranulomatous cholecystitis: histological study and classification. Pathol Res Pract, 1990; 186:383-90.
6. Birch PJ, Richmond I, Bennett MK. Xanthogranulomatous appendicitis. Histopathology. 1993; 22: 597-8.
7. Cozzutto C, Carbone A. The xanthogranulomatous process. Pathol Res Pract. 1988; 183: 395 -402.
8. Munichor M, Kerner H, Cohen H, et al. Xanthogranulomatous appendicitis : an incidental finding of localized pathology. Ultrastruct Pathol. 2000; 24:33-9.
9. Guo G, Greenson JK. Histopathology of interval (delayed) appendectomy specimens: strong association with granulomatous and xanthogranulomatous appendicitis. Am J Surg Pathol. 2003; 27:1147-51.
10. Mazziotti EF, Marley AL, Winthrop PG, et al. Histopathologic analysis of interval appendectomy specimens: support for the role of interval appendectomy. JPediatr Surg. 1997; 32:806-9.
11. T Maeda, M Shimada, T Matsumata, et al. Xanthogranulomatous cholecystitis masquerading as gallbladder carcinoma. Am J Gastroenterol. 1994; 89: 628 -30.
12. YF Chuang, TI Cheng, TC Soong, MH Tsou. Xanthogranulomatous appendicitis. Journal of the Formosan Medical Association. 2005; 104: 752-54.

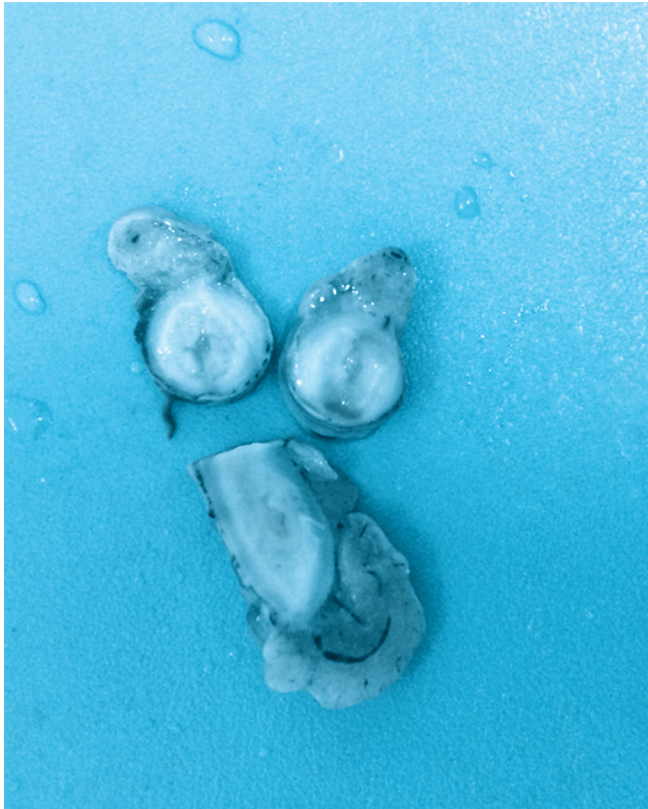

Figure 1 : Gross specimen showing focal yellowish discoloration of the mucosa and patent lumen




Figure 2: Microscopic view showing focal ulceration of mucosa ,collections of histiocytes with abundant granular eosinophilic cytoplasm (HE stain,X10)

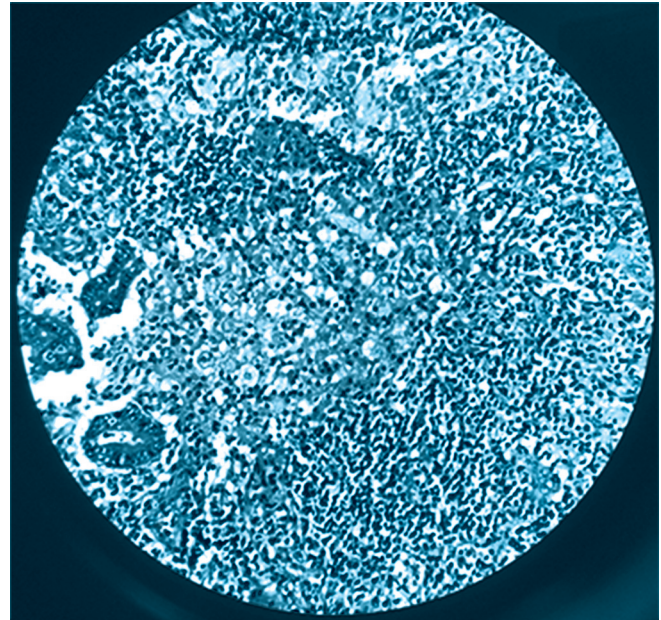


Figure 3: Microscopic view showing collections of histiocytes with abundant granular eosinophilic cytoplasm ,occasional foreign body type multinucleated giant cells admixed with variable amounts of lymphocytes , plasma cells and occasional eosinophils.(HE stain, X40)