

## Original Article

## Clinical and Epidemiological Profile of Herpetic Eye Disease in a Tertiary eye Care Center

**Chaudhary M**

Department of Ophthalmology, BP Koirala Lions Center for Ophthalmic Studies, Teaching Hospital Tribhuvan University

**Correspondence:** Dr Meenu Chaudhary

**E-mail:** drmeenu67@gmail.com

### Abstract:

**Introduction:** Herpes simplex virus (HSV) is the most common infective cause of blindness in developed countries, with a reported incidence of between 5.9 and 20.7 episodes per 100,000 persons each year. It remains the most common cause of unilateral corneal blindness worldwide. HSV ocular infections include conjunctivitis, blepharitis, epithelial infections like dendritic ulcer, geographic ulcer and punctate epithelial keratitis, stromal infections like disciform and necrotizing stromal keratitis, and iritis. Visual loss usually occurs from the cumulative effect of multiple recurrences.

**Methodology:** Hospital based prospective study was conducted for a period of one year (1st Jan 2015-31st Dec 2015) at B.P.koirala Lions Center for Ophthalmic Studies, IOM, Kathmandu, Nepal. All patients with symptoms and signs suggestive of herpes eye disease having decreased corneal sensation were included. Performa included demographic profile of patients, clinical pattern, presenting symptoms, visual acuity on presentation and treatment received.

**Results:** Incidence of Herpetic Eye Disease was 10.3%. Patients presented with mean age of  $36.63 \pm 16.94$  years. 59.23% patients presented in productive young adult age group of 16-45 years. Patients presented with chief complain of redness 38%, Diminution of vision 33%, Pain 12%, foreign body sensation 13% and photophobia in (4%) of cases. Clinical pattern was Blepheroconjunctivitis in 26%, Filamentary keratitis in 1%, dendritic ulcer in 22%, Geographical ulcer in 4%, disciform keratitis in 28%, Stromal keratitis in 11% and recurrent keratitis in 3% cases. Treatment received included topical Acyclovir in 54% cases, oral Acyclovir and topical steroids in 43 % cases and topical, oral acyclovir with topical steroids in 3 % cases. Visual acuity on presentation was 6/6- 6/18 in 59.23% of patients and only 8.47% cases had visual acuity  $>3/60$ .

**Conclusion:** Herpetic eye disease is a corneal blinding disease with varying clinical presentation. The recurrence rate was low in our study. But, recurrent nature of this disease and the treatment required to decrease this recurrence needs to be further studied.

**Key words:** Herpes simplex virus, dendritic ulcer, cornea, disciform keratitis, acyclovir

### Introduction

Herpes simplex virus (HSV) is the most common infective cause of blindness in developed countries, with a reported incidence of between 5.9 and 20.7 episodes per 100,000 persons each year.<sup>(1)</sup> Herpes simplex keratitis is a leading cause of corneal blindness worldwide resulting from an infection with the Herpes simplex virus type 1 [HSV- 1]. The virus produces a variety of clinical manifestation due to its ability to infect a host and establish an indefinite and latent presence in

the neuronal ganglia. Visual loss usually occurs from the cumulative effect of multiple recurrences. Each attack produces additional scarring, vascularisation and thinning. The major factors which dictate the severity of recurrent herpes are: immune response of the host, the viral strain, and treatment.<sup>(2)</sup> HSV is endemic in virtually every human society throughout the world, from urban to remote native tribes. Humans are the only natural reservoirs for HSV and there are close associations recognized between HSV-1 strains and historical human populations.<sup>(3)</sup>

HSV ocular infections include conjunctivitis, blepharitis, and epithelial infections like dendritic ulcer, geographic ulcer and punctate epithelial keratitis, stromal infections like disciform and necrotizing stromal keratitis, and iritis. A clinico-virological correlation study in Chile showed a 77% correlation using culture and polymerase chain reaction techniques in cases of epithelial keratitis, and a 20% correlation in stromal keratitis cases using polymerase chain reaction. HSK being a treatable ocular infection, clear documentation of its clinical and virological features is relevant in day-to-day clinical practice to diagnose the infection early and for instituting appropriate treatment strategies to control the disease<sup>(1)</sup>.

There are now eight recognized human herpes viruses: herpes simplex virus type 1 (HSV-1), HSV-2, varicella-zoster virus, cytomegalovirus, Epstein-Barr virus, human herpesvirus 6 (associated with roseola infantum), human herpesvirus 7 (associated with roseola infantum and febrile convulsions), and human herpesvirus 8 (associated with Kaposi sarcoma and lymphomas).<sup>(3)</sup>

The human herpes viruses are an important source of ophthalmic morbidity worldwide including cytomegalovirus retinitis in AIDS. Herpes simplex virus belongs to a family of viruses called Herpesviridae. They are composed of a central DNA core and a protein capsid with 162 hollow cylindrical capsomeres. This nucleocapsid is surrounded by an envelope forming a virus particle (virion) with an overall diameter of 130-180 nm. There are two types of HSV, namely, type 1 and 2. In general, type 1 causes infection above, and type 2, below the waist. Infection with HSV for the first time can develop at any age although most cases occur within the first few years of life. Salivary contamination from a person with silent salivary shedding of herpes labialis is the most common source of infection. However, primary HSV infection can also occur in other mucous membranes, including the conjunctiva. Primary ocular HSV infection most commonly manifests as blepharoconjunctivitis which is predominantly unilateral. The periorbital skin can develop intense blisters associated with conjunctivitis and blepharitis. Extensive spread on the facial skin can occur, particularly in eczematous individuals. The conjunctivitis is usually follicular although severe cases may develop pseudo-membranous reaction. Preauricular lymphadenopathy often accompanies the conjunctivitis. Keratitis develops a few days after conjunctival involvement in 30-50% of cases. The morphology of the corneal lesions varies from superficial punctate keratitis, microdendrites or frank dendritic ulceration. Stromal involvement is rare.<sup>(4)</sup>

The initial ocular infection may be mild. Visual morbidity results from recurrent keratitis, which leads to corneal scarring, thinning and neovascularisation. Although, recurrent disease may potentially occur through anterograde axonal spread from the trigeminal ganglion to the cornea, recent evidence suggests that HSV-1 in the cornea may be another source of recurrent disease. The pathogenesis and severity of HSK is largely determined by an interaction between viral genes encoded by the strain of HSV-1 and the makeup of the host's immune system. The pathogenesis of corneal scarring and vascularisation is uncertain but appears to be a complex interaction of various cytokines, chemokines and growth factors either brought in by inflammatory cells or produced locally in response to HSV-1 infection.<sup>(5)</sup>

In developing countries where prevalence of bacterial and fungal keratitis and associated ocular diseases is high, herpetic keratitis, although known to be present, is generally regarded as a less significant ophthalmic problem. The incidence of monocular blindness owing to corneal scarring and corneal opacities is estimated to be 1.5-2 million new cases every year. In the developing countries, the incidence of bacterial and fungal corneal ulcers has been estimated. The epidemiology of ocular involvement with HSV has not been well defined in developing countries despite the observations that in developed nations, this is the most frequent cause of corneal opacity.<sup>(6)</sup>

Thus, not much information is available regarding the visual impairment and morbidity owing to herpes simplex keratitis (HSK) in Nepal. Till date no documentation of epidemiology and clinical features of herpetic eye disease (HED) have been reported from Nepal. Hence, this study was conducted to characterize HSV keratitis as observed in Kathmandu, Nepal.

## Methods

This hospital based prospective study was conducted for a period of one year (1<sup>st</sup> Jan 2015- 31<sup>st</sup> Dec 2015) at B.P.Koirala Lions Center for Ophthalmic Studies, IOM, Kathmandu, Nepal. All patients with corneal disease with symptoms and signs suggestive of herpes keratitis and having decreased corneal sensation attending the general clinic, cornea clinic and Emergency of T.U. Teaching Hospital were included in the study. A Proforma was filled which included demographic profile (age and Sex) of patients, clinical pattern, presenting symptoms, visual acuity on presentation and treatment received. All the cases were examined by a cornea specialist under slit-lamp magnification. Clinical details on slit-lamp examination were recorded and diagnosis

of the stage of disease was noted in the case record. All the cases were enrolled after informed consent.

A definite diagnosis of epithelial keratitis was made when dendritic (seen as branching linear epithelial ulcer) or geographic ulcer (seen as a broad area of epithelial involvement with irregular angulated borders) was seen. Disciform keratitis was diagnosed in presence of central corneal stromal edema with or without keratic precipitates beneath the lesion. Stromal keratitis was diagnosed when deep layers of corneal stroma were diffusely infiltrated and in absence of other causes of keratitis, previous dendritic keratitis or loss of corneal sensation. Presence of mild stromal edema, medium-sized keratic precipitates, aqueous flare and cells, was clinically diagnosed as disciform keratitis (endothelitis).Keratouveitis was diagnosed when there was manifest significant corneal edema with or without vascularisation and marked signs of anterior uveitis. As it was difficult to clinically differentiate mild keratouveitis from endothelitis, for the purpose of analysis, some cases of Keratouveitis were clubbed together with endothelitis.

Patients with Bacterial, Fungal Corneal ulcers, Acanthamoeba keratitis, Mooren’s ulcers, Epidemic Keratoconjunctivitis were excluded from the study. Data analysis was done using SPSS 15.

Results

In our study of one year total number of patients presenting with corneal diseases in cornea clinic were 1263. Total no. of new cases was 475(37.6%) and old cases were 788 (62%). Out of these new cases at the cornea clinic total number of cases with Herpetic Eye Disease was 130 (10.3%). Patients presented with mean age of  $36.63 \pm 16.94$  years. The number of male patients with herpetic eye disease was 74(57%) in comparison to females which was 56 (43%). The male: female ratio was: 1.3:1.

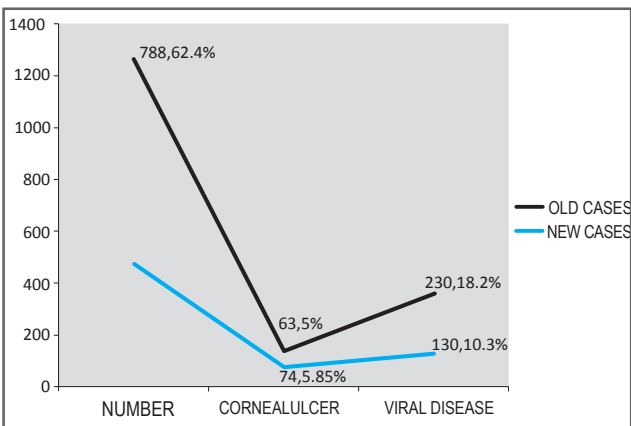


Figure 1: Incidence of HED in cornea clinic

Chart 1: Age and Sex distribution of patients with HED

Age (in years )	Male		Female	
	Number (N)	Percentage (%)	Number (N)	Percentage (%)
0-16	4	5.41%	7	12.5%
16-30	20	27.03%	21	37.5%
30-45	24	32.43%	12	21.43%
45-60	15	20.27%	11	19.64%
>60	11	14.86%	5	8.93%
Total	74	100%	56	100%

More number of patients presented in the age group of 16- 45 years ie 77 (59.23%) which is young adults, active and productive age group.

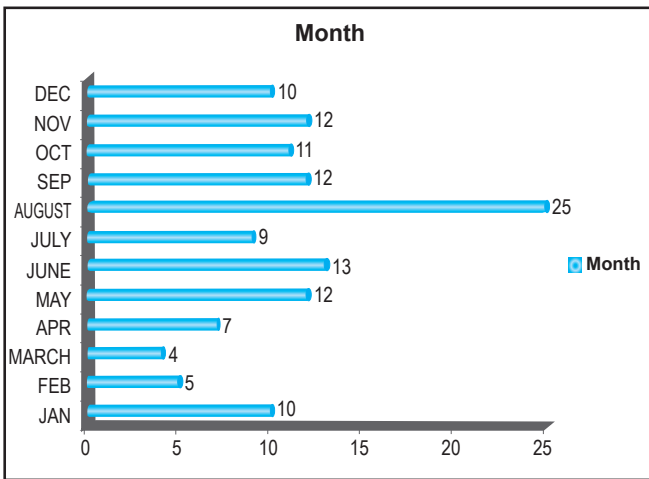


Figure 2: Seasonal variation

Chart 2: Chief complains at presentation

Serial No.	Symptoms	Number of cases (N)	Percentage (%)
1	Redness	49	38 %
2	Pain	16	12%
3	Diminution of vision	43	33%
4	Foreign Body sensation	17	13%
5	Photophobia	5	4%
	Total	130	100%

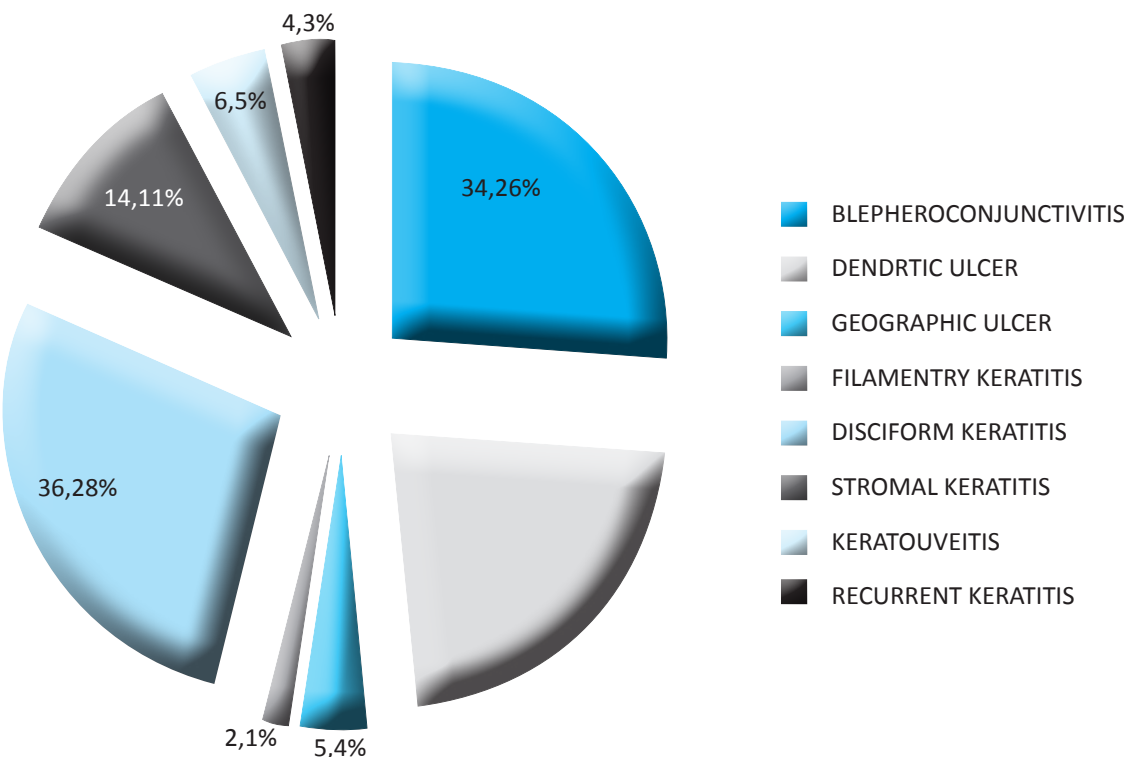


Figure 3: Clinical Pattern of HED

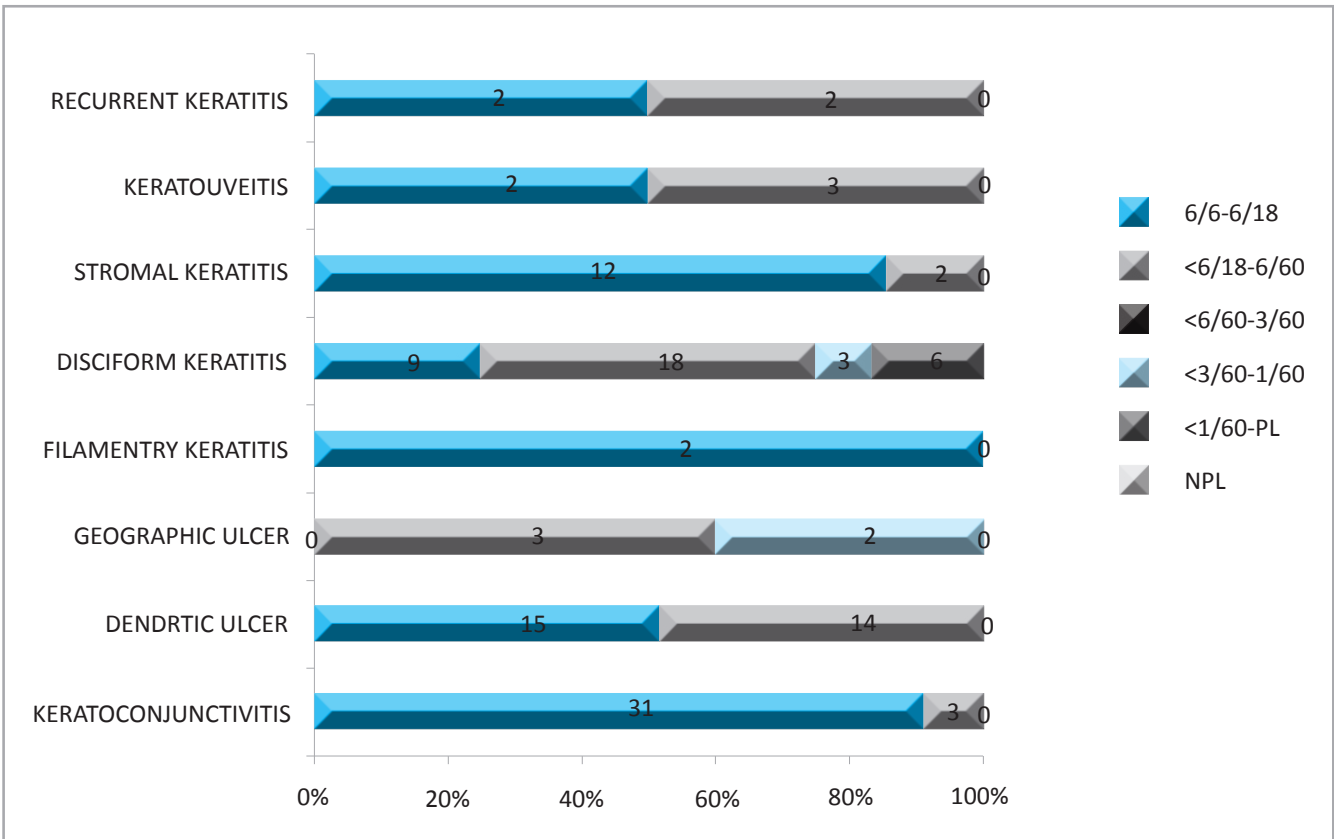


Figure 4: Visual Acuity on Presentation

## Treatment

Patients were treated with topical antiviral (Acyclovir) in (N=70), 54% cases, oral Acyclovir with topical steroids in (N=56), 43% cases and 3%, (N=4) cases were treated with topical and oral acyclovir and topical steroids according to clinical pattern of HED the patients presented with.

## Discussion

Most humans are infected with herpes simplex virus (HSV) type 1 in early childhood and remain latently infected throughout life. While most individuals have mild or no symptoms, some will develop destructive HSV keratitis. Ocular infection with HSV-1 and its associated sequelae account for the majority of corneal blindness in industrialized nations.<sup>(7)</sup> The epidemiological and clinical features of herpes simplex virus ocular infection in 130 patients were evaluated in this study. This is similar to a study done by Darougar S et al in which 108 patients with HED were observed.<sup>(8)</sup> The true incidence of herpes simplex keratitis and ocular morbidity may be difficult to determine in a given population as some episodes of the infections may go unnoticed by the patient or may have resolved by themselves.<sup>(6)</sup> Mean age of presentation in our study was 36.63±16.94. The mean age of the patients in a study by Kabra et al was 32 years in males and slightly lower for females, which was 29 years with no significant difference.<sup>(6)</sup> There are few studies that have estimated the age of HSV occurrence. Darougar et al studied primary ocular HSV infections between 1973 and 1980 in 108 patients,<sup>(8)</sup> wherein ages were represented with the mean age for the first episode of ocular HSV as being 25 years. Liesegang et al<sup>(9)</sup> found the mean age to be 37.4 years in a study of 122 patients which is again similar to our study.

N. Pramod et al study included 234 patients clinically suspected of having HSK, of which 159 were men and 75 were women (M / F = 2.1:1).<sup>(1)</sup> The mean age was 29 years and the range was 9 months to 65 years. In our study the male: female ratio was 1.3: 1 showing no preponderance of males unlike in N. Pramod et al study.

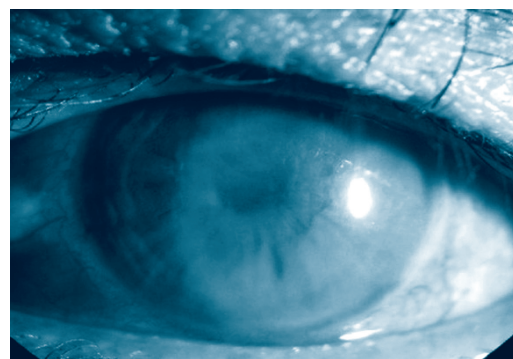
In our study more number of patients presented in the young adult group of 16-30 and 30-45 years group in both male (N= 44, 59.46%) and female (N=33, 58.92%) population. Study conducted in South India by N. Pramod et al found the mean age of patients

with ocular HSV to be 29 years.<sup>(10)</sup> Thus, the present evidence suggests that the common age for developing HSV is the younger adult group. Saini JS, Agarwala R study found the average age of patients to be 43.9 years with 67.5% of patients in the age group of 31-60 years.<sup>(11)</sup> Initial presentation of herpes simplex keratitis in K V Raju MS et al study was mainly in the age group 40 to 50 [26.7%].<sup>(2)</sup> The occurrence of HED was found to be nearly similar in both male and female population.

On analyzing the seasonal variation in our study, number of patients in all the seasons appeared to be the same, except in the month of August where some increase was seen, which was not significant. Kabra et al also analyzed the seasonal variations and as the climatic conditions of South India are more or less constant throughout the year, they did not find any clear seasonal pattern, although more cases were seen in the later part of the year.<sup>(6)</sup> Wishart et al in their study, though, found highest prevalence in June, but without any clear seasonal pattern during the rest of the year.<sup>(12)</sup> N. Pramod et al also found no seasonal variation in India.<sup>(10)</sup>

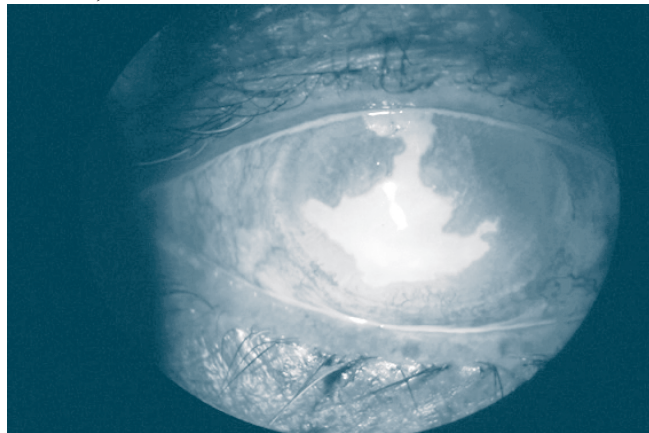
In our study patients presented with chief complaints of redness in (38%), Diminution of vision in (33%), Pain (12%), foreign body sensation in (13%) and photophobia in (4%) of cases. All the cases presented with unilateral presentation and no bilateral case was seen. The presenting symptoms in K V Raju et al study were redness [93.3%], dim vision [88.9%], pain [62.2%], photophobia [51.1%], lid swelling [48.8%], watering [53.3%], and least common was lid lesions [2.2%].<sup>(2)</sup> S Darougar et al also found symptoms like redness, watering, discharge, itching, irritation, and lid swelling to be the common symptoms of presentation whereas pain, photophobia, lid vesicles and ulcers, and blurred vision were less frequent in their study.<sup>(8)</sup>

### Photograph 1: Disciform Keratitis





**Photograph 2: Geographical Ulcer (Fluorescent dye stained)**



The different pattern of Clinical presentation in our study was Blepheroconjunctivitis in 26%, Filamentary keratitis in 1%, Dendritic ulcer in 22%, Geographical ulcer in 4%, Disciform keratitis in 28%, Stromal keratitis in 11% and recurrent keratitis in 3% cases . Kabra et al study had patients with clinical presentations as follows: 15.91% presented with dendritic ulcers, 4.09% with geographic ulcers, 53.64% with stromal keratitis, 17.73% with epithelial and stromal keratitis, and 8.64% with endothelitis.<sup>(6)</sup> KV Raju et al also described types of lesions as 53.4% cases of epithelial keratitis with SPK's 35.6% and dendritic lesions 17.8%. Stromal keratitis was 26.7% and endothelitis 17.8%. Only one [2.2%] patient presented with primary herpes.<sup>(2)</sup> The pattern of clinical presentation was not different from the various studies<sup>(9)</sup> reported in the literature. There was a slightly higher incidence of stromal keratitis in Kabra et al study and KV Raju et al study whereas our study had 11% cases of stromal keratitis. Our study showed higher frequency of disciform keratitis. In our study no case of primary herpes attended the cornea clinic. In our study recurrent attack with one episode during the follow up period was seen only in 3% of cases. Kabra et al have reported 41% patients with one recurrent attack during the follow-up period, 12% with two recurrent episodes, 5% with three recurrent episodes, and 2% with four or more recurrent episodes.<sup>(6)</sup> Thus, blindness due to herpes simplex keratitis ,mainly because of its recurrent nature, which leads to corneal scarring which was seen less in our study may be because of smaller follow up period.

There was a temporary visual morbidity on presentation in majority of patients with herpes simplex keratitis. 59.23% of patients presented with visual acuity of 6/6-6/18. 32.30% patients presented with <6/18-6/60. 3.85% and 4.62% patients presented with visual acuity of <3/60-1/60, 1/60 – PL respectively. In Kabra et al

study also extent of visual gain was: 62% had visual acuity of 20/40 or more and only 2% eyes had visual acuity less than 3/200. Though the patients initially had decreased visual acuity with the acute attack of disease, the majority of the patients maintained the final visual acuity of 20/40 or better, which corresponds to the Wilhelmus study who reported that 73% had visual acuity of 20/40 or better, 24% had visual acuity between 20/60 and 20/200, and only 3% had visual acuity worse than 20/200, after 5 years of follow-up.<sup>(6)</sup> In our study also 8.47% cases had visual acuity less than 3/60.

The treatment received by our patients included topical Acyclovir 54% cases, oral Acyclovir and topical steroids in 43 % cases and topical and oral acyclovir with topical steroids in 3 % cases. Higher number of cases received topical acyclovir as more number of patients had presented with epithelial keratitis (Blepheroconjunctivitis, Filamentary keratitis, dendritic and geographical ulcer). Oral acyclovir and topical steroids was also used more in our study due to higher frequency of disciform keratitis and stromal keratitis. Similarly Saini JS, Agarwala R et al used topical acyclovir and steroids accordingly for the clinical presentation of HED.<sup>(11)</sup> Knickelbein et al firmly established that topical corticosteroids in addition to a topical antiviral agent are effective in managing HSV stromal keratitis.<sup>(13)</sup> In our study also oral acyclovir was given in Disciform keratitis, recurrent cases and cases of keratouveitis . Roy W. Beck, et al in a study of 703 patients, who had an episode of ocular HSV disease during the year preceding the trial, demonstrated that oral acyclovir reduced the incidence of ocular recurrences during a 12-month treatment period by nearly half.<sup>(14)</sup>

According to Lucy Zhu,<sup>(15)</sup> antiviral agents are the mainstay of HSV therapy. Acyclovir is a purine nucleoside analogue acting selectively against HSV without causing substantial toxic effects on uninfected cells. Antiviral nucleosides at large work by interfering with viral DNA synthesis during transcription of the viral genome to inhibit HSV replication. Oral therapy has the advantage of no ocular surface toxicity and systemic antiviral activity. As such, long-term use of an oral antiviral medication at a lower dose would be appropriate for patients experiencing recurrent ocular HSV.<sup>(15)</sup> In cases of active herpetic epithelial keratitis, topical corticosteroids are contraindicated. This is because topical steroids inhibit normal immune defense mechanisms. Treatment for stromal keratitis employs topical corticosteroids accompanied by a prophylactic antiviral drug. The Herpetic Eye Disease

Study determined that a tapering regimen of topical corticosteroid (1% prednisone for the first five weeks followed by 0.125% prednisone for the next five weeks) with a topical antiviral agent was able to significantly reduce the duration of stromal inflammation and progression of herpetic stromal disease.<sup>(15)</sup> Similarly, endotheliitis is treated with a combined corticosteroid and antiviral therapy.<sup>(15)</sup>

## Conclusion

Herpetic keratitis is a blinding disease with varying presentation. The incidence of herpetic keratitis was higher than bacterial or fungal ulcer in our hospital. Patients also presented with varying type of visual acuity and only a small group had vision less than 3/60. But, recurrent nature of this disease and the treatment required to decrease this recurrence needs to be further evaluated.

## Acknowledgement

To all my patients who helped me to conduct this study.

## Conflict of interest: None declared

## References

1. Pramod NP, Rajendran P, Kannan KA, Thyagarajan SP. Herpes simplex keratitis in South India: Clinico-virological correlation. *Jpn J Ophthalmol* [Internet]. 1999 [cited 2016 Oct 13]; 43(4):303–7. 2.
2. K V Raju MS, Jyothi PT MS SIM. Clinical Profile of Herpes Simplex Keratitis. *Ksoss J*. 2011;XXIII(1):33–6.
3. TJ L. Herpes simplex virus epidemiology and ocular importance. *Cornea* [Internet]. 2001 [cited 2016 Oct 10]; 20(1):1–13. Available from:
4. Suresh PS, Tullo AB. Herpes simplex keratitis. *Indian J Ophthalmol* [Internet]. Medknow Publications and Media Pvt. Ltd.; 1999 Sep [cited 2016 Oct 13]; 47(3):155–65. Available from
5. Kaye S, Choudhary A. Herpes simplex keratitis [Internet]. *Progress In Retinal And Eye Research*. 2006. p. 355–80.
6. Kabra A, Lalitha P, Mahadevan K, Prajna NV, Srinivasan M. Herpes simplex keratitis and visual impairment: a case series. *Indian J Ophthalmol*. 2006; 54(1):23.
7. Al-Dujaili LJ, Clerkin PP, Clement C, McFerrin HE, Bhattacharjee PS, Varnell ED, et al. Ocular herpes simplex virus: how are latency, reactivation, recurrent disease and therapy interrelated? *Future Microbiol* [Internet]. NIH Public Access; 2011 Aug [cited 2016 Sep 28]; 6(8):877–907.
8. S Darougar, M S Wishart and NDV. Epidemiological and clinical features of primary herpes simplex virus ocular infection. *Br J Ophthalmol*. 1985; 69(1):2–6.
9. TJ L. Epidemiology of ocular herpes simplex: natural history in Rochester, Minn, 1950 through 1982. *Arch Ophthalmol*. 107(8): 1160–5.
10. Pramod NP, Rajendran P, Kannan KA, Thyagarajan SP. Herpes simplex keratitis in South India: Clinico-virological correlation. *Jpn J Ophthalmol*. 1999 ;43(4):303–7.
11. Saini JS, Agarwala R. Clinical pattern of recurrent herpes simplex keratitis. *Indian J Ophthalmol*. 1999; 47(1):11–4.
12. Wishart MS, Darougar S, Viswalingam ND. Recurrent herpes simplex virus ocular infection: epidemiological and clinical features. *Br J Ophthalmol* [Internet]. 1987;71(9):669–72.
13. Knickelbein J, Hendricks R. Management of herpes simplex virus stromal keratitis: an evidence-based review. *Surv ophthalmology* [Internet]. 2009 [cited 2016 Oct 10]; 54(2):226–34.
14. Dr. Roy W. Beck at the Jaeb Center for Health Research, 3010 E. 138th Ave., Suite 9, Tampa FL 33613., Kirk R. Wilhelmus, M.D., M.P.H., Roy W. Beck, M.D., Ph.D. P, S. Moke, M.S.P.H., Chandler R. Dawson, M.D., Bruce A. Barron MD, Dan B. Jones, M.D., Herbert E. Kaufman M. Acyclovir for the Prevention of Recurrent Herpes Simplex Virus Eye Disease. *N Engl J Med*. 1998; 339:300–6.
15. Zhu L, Zhu H. Ocular herpes: the pathophysiology, management and treatment of herpetic eye diseases. *Virol Sin*. 2014; 29(6):327–42.