

Allergic Bronchopulmonary Aspergillosis with massive hemoptysis mimicking pulmonary tuberculosis

Paudel K¹, Adhikari S¹, Pant P²

¹Institute of Medicine, Maharajgunj Medical Campus, Tribhuvan University, Kathmandu, Nepal

²Department of Internal Medicine, Institute of Medicine, Maharajgunj Medical Campus, Tribhuvan University, Kathmandu, Nepal

Correspondence: Kumar Paudel

E mail: kumarpaudel01@gmail.com

Abstract

Allergic bronchopulmonary aspergillosis (ABPA) is a type II hypersensitivity lung disease induced by bronchial colonization of fungus, *Aspergillus fumigatus* that commonly occurs in patients with asthma or cystic fibrosis. We present a case of 65-year-old Brahmin man, non smoker and non atopic who presented with increasing hemoptysis, initially suspected as pulmonary tuberculosis and later diagnosed as ABPA. He was managed with oral prednisolone 0.5mg/kg/day for 14 days followed by gradual tapering over the period of 6 weeks with remarkable response.

Key words: Allergic Bronchopulmonary Aspergillosis, Tuberculosis, Hemoptysis

Introduction

Hemoptysis refers to bleeding from the respiratory tract at or below the larynx. Hemoptysis is often a dreadful symptom for patients and is a manifestation of significant underlying tracheobronchial disease. The amount of hemoptysis can be quantified from small blood tinged to massive. Massive hemoptysis is variably defined. Wedzicha et al defined massive haemoptysis as expectoration of blood ranging from 200 to 600 ml over 24 to 48 hours.¹

The commonest causes of hemoptysis include acute and chronic bronchitis, pneumonia, tuberculosis and lung cancer.² Tuberculosis comprises the major cause of hemoptysis in the developing world.³ Despite tuberculosis shares the major burden of cause of hemoptysis, here we present the case of allergic bronchopulmonary aspergillosis (ABPA) presenting with massive hemoptysis. This is the first case of ABPA with hemoptysis reported so far from Nepal.

Aspergillus fumigatus is a fungus commonly implicated in aspergillosis. It can cause wide variety of clinical presentation varying from aspergilloma, allergic bronchopulmonary aspergillosis, lung collapse to a aggressive necrotizing aspergillosis in immunocompromised people.

Allergic bronchopulmonary aspergillosis (ABPA) is a T helper cell 2 mediated hypersensitivity lung disease owing to colonization by *Aspergillus fumigatus* commonly occurring in susceptible patients with asthma or cystic fibrosis. The clinical presentation of ABPA can range from mild bronchospasm to fibrotic

parenchymal disease. It is now being increasingly diagnosed probably with the advancement of several diagnostic test and liberalization of diagnostic criteria. The criteria for diagnosis of ABPA for the patients with cystic fibrosis are, asthma, immediate cutaneous reaction to *A. fumigatus*, total serum IgE concentration (>1000 ng/ml), elevated *A. fumigatus*-specific serum IgE levels, precipitating antibodies to *A. fumigatus* in the serum, peripheral blood eosinophilia >500/cmm (not essential for diagnosis), chest Roentgenographic infiltrates (not essential for diagnosis), central bronchiectasis.⁴ The common features of ABPA namely cough, fever, hemoptysis and chest infiltrates are often perceived as the features of pulmonary tuberculosis.

Case Report

A 65 year old gentleman, presented to Tribhuvan University Teaching Hospital (TUTH) emergency with massive hemoptysis for duration of 1 day. The hemoptysis commenced 12 days back prior to his presentation, which was bright red in color and half a cup per day. The amount significantly increased for 12 hours prior to the presentation in emergency. It was associated with occasional chest pain more on right side, which aggravated while coughing.

He also had productive cough for same duration, with yellowish sputum tinged with blood. With these symptoms he was suspected for pulmonary tuberculosis and was prescribed Anti-tubercular therapy in the primary care center. However, symptoms persisted, so he was referred to TUTH for review of specialist.

He had pulmonary tuberculosis 4 years back for which he received the anti tubercular therapy for 6 months which resolved his symptoms. He denied of having orthopnea, paroxysmal nocturnal dyspnea, palpitations or significant weight loss. He is a farmer , non smoker and non alcohol consumer.

At presentation, he was dyspneic. On general examination he was ill looking but was conscious and well oriented. His axillary temperature was 37.2 degree Celsius. Blood pressure measured on right arm in sitting position was 100/60 mm of Hg. Pulse rate was 102 beats per minute. Saturation was 97% in room air. Respiratory rate was 26 per minute. On head to toe examination, there was no pallor, icterus, cyanosis, clubbing, edema, dehydration and no lymphadenopathy. On auscultation, breathe sound was normal vesicular with crackles audible over the bilateral basal lung fields. All other system examination was unremarkable.

His hematological investigations revealed complete blood count of 6610/cumm with differential count of 55% neutrophil , 22% lymphocytes and 23% eosinophil, platelet count of 155000 and ESR of 56. Prothrombin time was of 10 seconds (control=10 second). ANA, HCV, HBsAg, HIV were negative. Liver function test, renal function test were within normal limit. With these investigations patient was admitted in respiratory ward for further evaluation.

Urine routine and microscopic examination was unremarkable, and gram stain was negative for bacteria. There was no bacterial or fungal growth in sputum and blood culture.

X-ray chest showed bilateral lower lobe infiltrates. The cardiac silhouette was normal.(Figure 1)

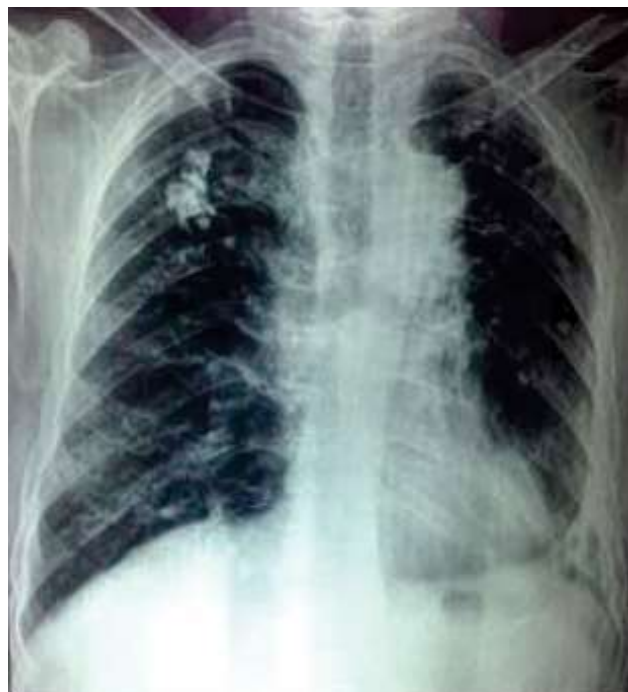

Figure 1: Bilateral lower lobe infiltrates

A High Resolution Computed Tomography scan of chest demonstrated non homogenous opacity over right lower lobe with central bronchiectatic changes .There was no mediastinal lymphadenopathy.

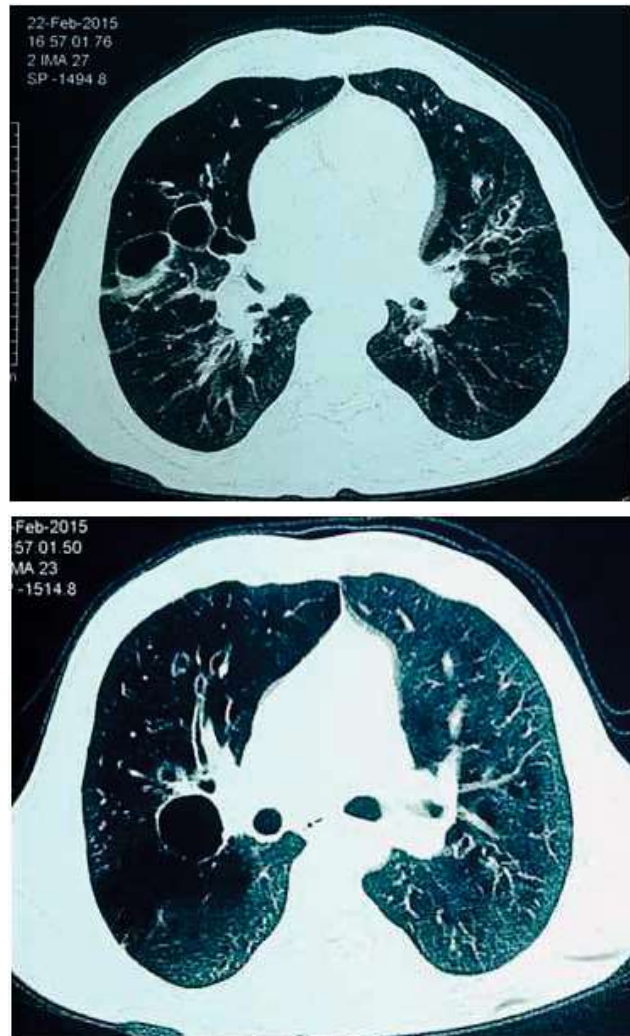


Figure 2: High Resolution Computed Tomography scan of chest demonstrated non homogenous opacity over right lower lobe with central bronchiectatic changes.

The patient was investigated for pulmonary tuberculosis and bronchogenic carcinoma however the sputum AFB and cell cytology was negative.

As the initial treatment did not relieve the symptoms he was further evaluated for ABPA. The total serum IgE level was 832 IU/ml, Fumigatus-specific IgE level was 20.9 IU/ml and the aspergillus antibody test was also positive. Spirometry showed minimal airflow limitation. With these findings, a diagnosis of ABPA was made and the patient was then started on oral prednisolone (0.5mg/kg per day), which mitigated his hemoptysis in 3 days and got resolved entirely in 2 weeks. Prednisolone was then tapered for 6 weeks and stopped. He is now under regular follow up and is free of any respiratory symptoms. In 6 month follow up, his serum IgE level returned to 180 IU/ml .

Discussion

Allergic bronchopulmonary aspergillosis (ABPA) is commonly found associated in asthmatic patients. ABPA in patient without atopy is very rare.^{5,6} ABPA presents with repeated exacerbations and remissions. The clinical and radiological findings depend on the stage of its presentation. ABPA can mimic pulmonary tuberculosis in terms of X-ray findings (fibrotic changes) to clinical symptoms namely hemoptysis, cough and fever.⁷ This may lead to misdiagnosis and untoward treatment with anti tubercular drugs, while being pulmonary pathology continuing to progress relentlessly and culminating in advance fibrotic lung disease. This necessitates high index of suspicion for early diagnosis of ABPA in a patient presenting with a recurrent hemoptysis.

A study of Elkington PT et al revealed the metalloproteinase expression by the human airway epithelial cells being upregulated as a consequence of mycobacterium tuberculosis infection.⁸ This causes destruction of bronchial collagen fibers leading to brochiectatic changes, cavity formation, impaired ciliary activity and mucus impaction which further predispose to recurrent colonization by the fungus like aspergillus. In our patient with prior tuberculosis, the pathogenesis of developing ABPA was presumably via the same mechanism.

In ABPA patients, chest roentgenogram may be normal or it may show various infiltrate patterns mostly in upper and middle lobes. Homogenous fleeting shadows is characteristic features seen in ABPA.^{9, 10}

Though being an expensive tool in an resource constrained settings, HRCT is a promising tool for early diagnosis of ABPA. Central brochiectatic changes with or without high attenuation mucus (HAM) and peri hilar radio opacity in HRCT strongly favor ABPA.¹¹ It is important especially when ABPA develops in previously affected lung parenchyma.

In the low and middle income countries (LMICs), where prevalence of tuberculosis is high, and with limited diagnostic tools, the symptoms like hemoptysis, fever and cough are many a times attributed to pulmonary tuberculosis, which lead to late or misdiagnosis of ABPA. Though, pulmonary tuberculosis and ABPA are similar clinically, the management of these is remarkably different.

Although ABPA was previously assumed to be disease with difficulty treatment, with advancement of diagnostic approach, it can be treated successfully if diagnosed and intervened early. The initial management with prednisolone 0.5 mg/kg/day for 14 days followed by gradual tapering over the period of 6-8 weeks has shown a promising response.¹² Oral itraconazole, appears to be an effective adjunctive therapy with synergistic action without any significant side effects with steroids.¹³ Chest physiotherapy and postural drainage of sputum enhance the early resolution of symptoms. The treatment response can be monitored by assessing improvement in

symptoms like hemoptysis, sputum production, fever, chest tightness and clearance of radiological infiltrates as seen in our patient. Regular IgE testing helps to know the disease control and dose adjustment. The early diagnosis of ABPA and treatment can significantly reduce the healthcare related cost due to repeated hospital visits, repeated investigation and unnecessary antibiotics.

Conclusion

ABPA can manifest in post tubercular patient without history of atopy or cystic fibrosis. ABPA should be considered in patients with prolonged, Dyspnea and hemoptysis. A short term treatment with prednisolone has shown significant improvement.

Conflict of interests: None Declared

References:

1. Wedzicha JA, Pearson MC. Management of massive haemoptysis. *Respiratory medicine*. 1990; 84(1):9-12.
2. Bidwell JL, Pachner RW. Hemoptysis: diagnosis and management. *American family physician*. 2005; 72(7):1253-60.
3. Abal AT, Nair PC, Cherian J. Haemoptysis: aetiology, evaluation and outcome—a prospective study in a third-world country. *Respiratory medicine*. 2001; 95(7):548-52.
4. Tillie-Leblond I, Tonnel AB. Allergic bronchopulmonary aspergillosis. *Allergy*. 2005; 60(8):1004-13.
5. Shin JE, Shim JW, Kim DS, Jung HL, Park MS, Shim JY. Case of seropositive allergic bronchopulmonary aspergillosis in a 10-year-old girl without previously documented asthma. *Korean journal of pediatrics*. 2015; 58(5):190-3.
6. Glancy JJ, Elder JL, McAleer R. Allergic bronchopulmonary fungal disease without clinical asthma. *Thorax*. 1981; 36(5):345-9.
7. Agarwal R, Gupta D, Aggarwal AN, Behera D, Jindal SK. Allergic bronchopulmonary aspergillosis: lessons from 126 patients attending a chest clinic in north India. *Chest*. 2006; 130(2):442-8.
8. Elkington PT, Emerson JE, Lopez-Pascua LD, O'Kane CM, Horncastle DE, Boyle JJ, et al. Mycobacterium tuberculosis up-regulates matrix metalloproteinase-1 secretion from human airway epithelial cells via a p38 MAPK switch. *Journal of immunology (Baltimore, Md : 1950)*. 2005; 175(8):5333-40.
9. Hinson KF, Moon AJ, Plummer NS. Broncho-pulmonary aspergillosis; a review and a report of eight new cases. *Thorax*. 1952; 7(4):317-33.
10. Shah A. Aspergillus-associated hypersensitivity respiratory disorders. *The Indian journal of chest diseases & allied sciences*. 2008; 50(1):117-28.
11. Kaur M, Sudan DS. Allergic Bronchopulmonary Aspergillosis (ABPA)-The High Resolution Computed Tomography (HRCT) Chest Imaging Scenario. *Journal of clinical and diagnostic research : JCDR*. 2014; 8(6):Rc05-7.
12. Vaughan LM. Allergic bronchopulmonary aspergillosis. *Clinical pharmacy*. 1993; 12(1):24-33.
13. Greenberger PA, Bush RK, Demain JG, Luong A, Slavin RG, Knutsen AP. Allergic Bronchopulmonary Aspergillosis. *The journal of allergy and clinical immunology In practice*. 2014; 2(6):703-8.