

Prevalence of Dental Deep bite in Nepalese Adolescents of Kathmandu Valley

Yadav R, Shrestha BK, Yadav N¹, Basel P²

Department of Dentistry, Institute Of Medicine, Tribhuvan University Teaching Hospital

¹ Consultant, Prosthodontics, ²Assistant Professor, Department of Community Medicine and Public Health, IOM, TUTH

Correspondence to: Dr. Rajiv Yadav,

Email: drrajivresearch@gmail.com

Abstract

Introduction: Deep bite is defined as vertical overlap of upper teeth on the labial surface of lower teeth in centric occlusion when exceeds the normal range of 1-2 mm. Deep bite can be classified into skeletal and dental deep bite. Skeletal deep bites are usually of genetic origin. Dental deep bites occur due to over-eruption of anterior teeth, infra-occlusion of molars or its combination. It may jeopardize the periodontal support, occlusion itself or TMJ.

Methods: It is a cross-sectional descriptive study. The study population included 14-18 year-old adolescents studying in high school of all three districts of Kathmandu Valley. An evaluation form was developed categorizing different levels of deep bite following WHO guidelines 1985 and accordingly data were recorded on it.

Results: Out of 935 screened students 80.4% had Normal bite and 19.6% had Deep bite. 2.7% had Severe deep bite but no trauma to palatal mucosa whereas 3.8% had traumatic bite. Normal over bite in Female was 84% and male was 77.7%. Deep bite in male was 22.3% and female was 16%.

Conclusion: The prevalence of dental deep bite was found to be 1/4th of normal overbite in Nepalese adolescents of Kathmandu valley. Prevalence of severe deep bite with trauma to palatal mucosa was relatively higher than with trauma. Females showed higher prevalence of normal overbite than males whereas males showed higher prevalence of deep bite than females.

Key words: Deep bite, palatal mucosa, Traumatic bite, High school students, Prevalence

INTRODUCTION

Deep bite is one of the frequently seen malocclusion next to crowding. It is defined as vertical overlap of upper teeth on the labial surface of lower teeth in centric occlusion when exceeds the normal range of 1-2 mm.¹ Upadhyay & Nanda define overbite as the amount and percentage of overlap of the lower incisors by the upper incisors. An ideal overbite ranges from 5-25% overlap. This deep bite is either described in millimeters or as the percentage of mandibular together incisor crown length overlapped by maxillary central incisors. Since the crown length of the lower incisors significantly varies in individual, a notation of the overbite in percentage

is more descriptive and desirable.² Deep bite can be classified into skeletal and dental deep bite. Skeletal deep bites are usually of genetic origin. This kind of deep bite is caused by upward and forward rotation of the mandible and can be worsened by downward and forward inclination of the maxilla. On the other hand, dental deep bite is characterized by absence of any skeletal complicating features that are seen in skeletal deep bites. Dental deep bites occur due to over eruption of anterior teeth or infra-occlusion of molars or combination.³ Factors associated with the development of deep bite are: Molar infra occlusion, incisor supra occlusion, excessive over jet, canine position, mesiodistal width of the anterior teeth, incisor

angulation, molar cusp height, failure of age-related natural opening of the deep bite, mandibular ramus height, and vertical facial type.⁴ It is said to be one of the most perpetuating and damaging malocclusions. It may jeopardize the periodontal support, occlusion itself or TMJ. The excessive overbite is a complex orthodontic problem that may involve a group of teeth or whole dentition, alveolar bone of maxillary and mandibular basal bones, and/or soft tissue of the face. The term “overbite” applies to the distance which the maxillary incisal margin closes vertically past the mandibular incisal margin. The term “closed bite” describes condition of excessive overbite, where the vertical measurement between the maxillary and mandibular incisal margins is excessive when the mandible brought into habitual or centric occlusion. Closed bite is excessive overbite resulting from loss of posterior teeth. Excessive overbite is most prevalent in the mixed dentition and is a self-correcting transient malocclusion. Open bite is comparatively more prevalent in the deciduous dentition and tends to disappear in the later mixed dentition. A simple deep bite is localized to the teeth and alveolar processes. In this type of deep overbite, the problem lies mainly within the dentition. Dental deep bite occurs due to over-eruption of anteriors or infraocclusion of molars. The result may be labial version of the upper incisors and impingement of the lowers into the palatal mucosa known as “Traumatic bite. This kind of deep bite is characterized by the absence of any skeletal complicating features which are seen in skeletal deep bites. In the mandibular dentition, it may manifest as a deep curve of spee or are versecurve of spee in the maxillary dentition. These patients frequently show temporomandibular dysfunction and a limited range of functional occlusal movements. Complex deep bite is a deep bite associated with basic skeletal features with which the alveolar process cannot cope. A skeletal type of overbite may be due to either malrelationship of alveolar bones and/or underlying mandibular or maxillary bones or to an overgrowth or undergrowth of one or more alveolar segments. The diminished anterior vertical height of the face is also an important criterion for diagnosis of skeletal deep overbite. Complex deep bite is frequently associated with class II div 2 and occasionally with Class III.⁵ According to a study conducted by Proffit and Fields (2007), “overbite more than 5 mm is found in nearly 20% of the children and 13% of the adults”. Subjects with mild deep bite typically require no correction, unless the patient appeals correction for esthetics. However, severe overbite, considered as a clinical problem, should be corrected through orthodontic or orthosurgical intervention.

Severe overbite may affect the temporomandibular joint, cause periodontal problems and tooth wearing, as well as traumatizing the incisive papilla or interfering with mastication function.⁶ Maintenance of a corrected deep bite is most important challenges for orthodontists. When no accurate identification of the etiological factors is performed, treatment relapse is common.⁷ Bydass et al. Studied the effect of the depth of curve of spee on overbite and over jet. Increased overbite was observed in the deep curve of spee caused by extruded lower anterior teeth. Overbite could affect the maxillary and mandibular morphology and was associated with a decreased gonial angles.⁸ El-Dawlatly et al. evaluated skeletal and dental variables in patients with deep bite malocclusion and showed that deep bite has multifactorial etiology in which an exaggerated curve of spee and a decreased gonial angle were the greatest contributing factors.⁹ Despite the fact that prevalence of deep bite has been evaluated by many studies in different part of the world, similar situation may or may not be with orthodontic patients in Nepal. Hence this study was proposed.

Methods

It is a cross-sectional descriptive study. The study population included 14-18 year-old adolescents studying in high school of all three districts of Kathmandu Valley. Multistage sampling process was adapted for study sample and final sample size of 938 was derived out of 1097 screened that met the inclusive criteria. *Exclusion criteria:* Subjects with craniofacial anomalies (clefts and syndromes) and non-Nepali nationals were excluded from the study). *Clinical examination:* students were examined at the schools, in a quiet classroom without external interference, under natural or artificial illumination. The examination lasted approximately 15 minutes per child, following the World Health Organization (1985) guidelines.¹⁰ The assessment of dental occlusion was carried out using latex gloves, dental mouth mirrors, and mill metric rulers. An evaluation form was developed categorizing different levels of deep bite. Level of deep bite was recorded as Normal bite < 3.5mm, Deep Bite > 3.5mm, severe deep bite with no trauma to Palatal mucosa, Traumatic bite (severe deep bite causing trauma to Palatal mucosa). Students were examined by using dental probe and plane mouth mirror. Sufficient numbers of autoclaved instruments were made available to avoid the interruption during the study. After each day of examination, the entire instruments were autoclaved. *Quality assurance:* Training and calibration of examiner: Oral examination was performed by two trained and calibrated examiners.

Before the survey, 60 students were examined by each of the two investigators to assess inter-examiner reliability and, Kappa values for both the examiners were found to be 0.87 and 0.88 respectively. Ethical consideration: An ethical clearance was obtained from the Ethical Review Board of IOM [Reference: 224(6-11-E)²/074/075]. Each study individual was informed about the objective and benefit of the study. The informed consent form was signed to ensure consent of each study individual.

Statistical Analysis

Firstly, data were coded and entered into Excel sheet. To maintain the data quality (validity) rechecking and cross checking were done during data entry phase. After the entry of the data to excel sheet necessary data cleaning were done. Secondly, data were transformed into SPSS16.0 version where further cleaning, coding, recoding, cross checking, processing and analysis was done.

Results

Out of 938 selected students 80.4% had normal bite (with 95% CI of 0.78, 0.82) and 19.6% had deep bite (with 95% cl of 0.16, 0.21). (Fig.1& Table: 1). Looking at severity of deep bite and its relation to palatal mucosa 2.7% (with 95% Cl of 0.016, 0.037) had contact with lower incisor but no trauma where as 3.8%(with 95% CI of 0.025, 0.050) had traumatic bite. (Fig.2 & table: 2).Female had more normal bite in compared to male with female showing 84% and male 77.7%of prevalence where as male showed higher prevalence of deep bite scoring 22.3% and female 16% respectively. (Fig.3 & table: 3).

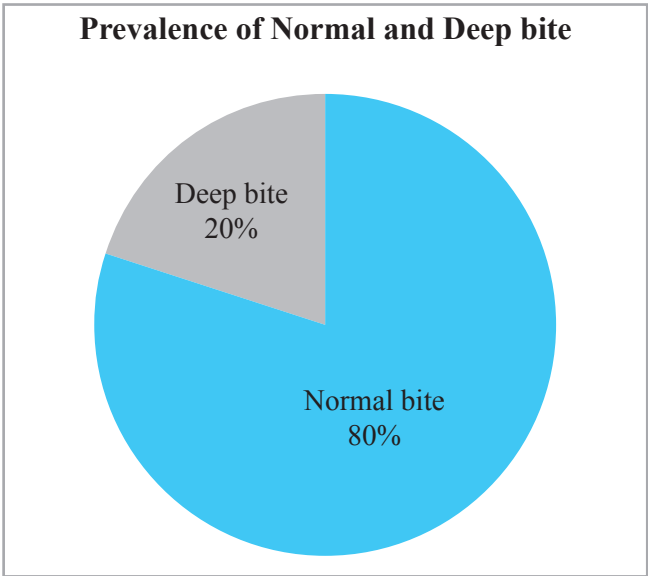


Fig. 1 : Prevalence of Normal and Deep bite

Table 1: Prevalence of Normal and Deep bite with 95% CI

	Bite type	Frequency	Percent
Valid	Normal bite	752	80.4(0.78, 0.82)
	Deep bite	183	19.6(0.16, 0.21)
	Total	935	100.0

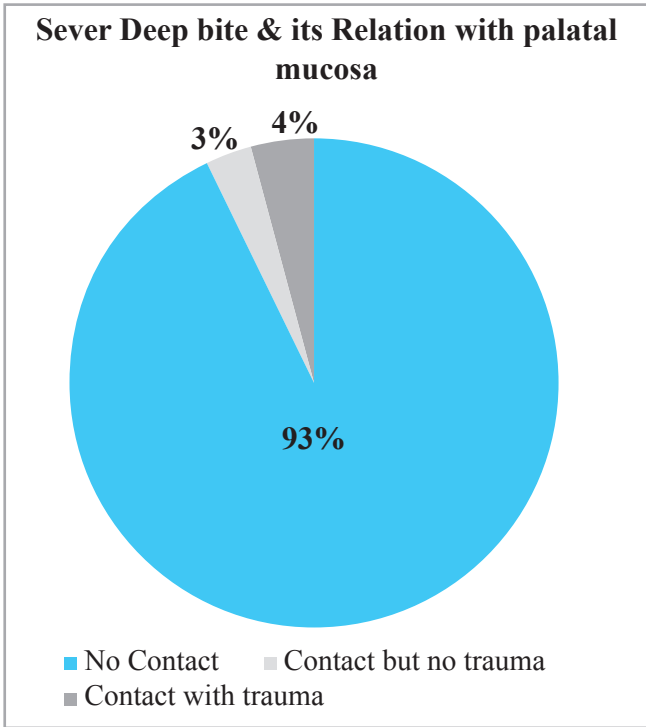


Fig. 2: Sever Deep bite & its Relation with palatal mucosa

Table 2: Relation with palatal mucosa with 95% CI

	Mucosal contact	Frequency	Percent
Valid	No contact	877	93.5(0.919, 0.950)
	Contact but no trauma to Palatal mucosa	25	2.7(0.016, 0.037)
	Contact with trauma to palatal mucosa (Traumatic Bite)	36	3.8(0.025, 0.050)
Total		938	100.0

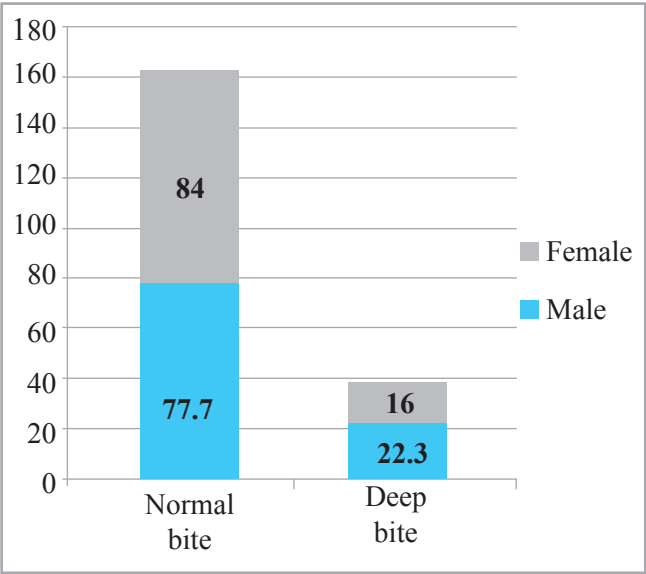


Fig. 3 Over bite Distribution by Gender

Table 3:Overbite distribution by sex

			Overbite		Total
			Normal bite	Deep bite	
Sex	Male	Count	412	118	530
		% within Sex	77.7%	22.3%	100.0%
	Female	Count	340	65	405
		% within Sex	84.0%	16.0%	100.0%
Total		Count	752	183	935
		% within Sex	80.4%	19.6%	100.0%

Discussion

Meer Z. *et al* (2016) showed that open bite (7.2%) was found less common than deep bite(21%).¹¹A1-Hummayani reported an identical pattern of anterior open bite and deep bite prevalence.¹² Erum and Fida (2008) found that 48.7%, 17.9%and 3.8% of Pakistani patients, had mild, moderate and severe deep bite respectively¹³ which is same as our study on Nepali patients where severe deep bite with trauma to palatal mucosa was recorded as 3.8%. Naeem *et al.* (2008) found that 76% of Pakistani patients showed varying values of deep bite. There was difference in prevalence of deep bite between males and females, 84% and 80% of males and females had deep bite respectively which is quite similar to our studies with male showing more deep bite than female.¹⁴Gabris*et al.*(2006) reported that the prevalence of deep bite varied from 11% to 26.1 % in adult populations.¹⁵ which is similar to our studies with percentage of deep bite being 20%. Celikoglu *et al.* (2010) also reported that anterior deep bite was more

current with Angle’s Class II (79%), followed by Class I (14.5%) and Class II (6.3%)respectively.¹⁶Helm 1968, found that deep bite was present in (22.7%) of Danish boys and(14.5%) of girls¹⁷ which is quite similar to our studies with male showing more deep bite than female. Sassouni and Nanda (1964) found that deep over bite was associated with more horizontal mandibular plane than average.¹⁸ Sandeep *et at.* (2012) found deep bite to be in approx 32%cases in their study. It is very high as compared to studies done in Nigerian where normal overbite relation was found to be more. Only 9.8% patients were having deep bite in the study done by Ajayi in Nigeria. The difference may be due to differences in facial growth pattern and racial differences. There was significant gender difference in deep bite which was found to be more in males as compared to females in our sample.¹⁹ Muppa, *et at.*(2013) In overall population when the eight malocclusion traits were compared, anterior crowding showed the highest incidence (27.37%) followed by deep bite (20.55%).²⁰Aniket H. *et.al*(2013)found increased overbite was recorded in 244 (43.6%) of the patients and mostly observed in males (P<0.002).²¹Oliveira *et al.* also found a low prevalence of deep overbite (5%) in Down Syndrome children. Normally these children have a high palate, hypertrophy of the tonsils, hypotonia and nasal obstruction, which lead to mouth breathing and therefore tend to exhibitan anterior open bite instead of a deep overbite.²²

Conciusion

The prevalence of normal over bite was found to be 80.4 % (with 95% CI of 0.78, 0.82) where as Deep bite was 19.6% (with 95% CI of 0.16, 0.21).The prevalence of severe deep bite with no trauma to palatal mucosa was 2.7% (with 95%CI of 0.016, 0.037) where as prevalence of traumatic bite was 3.8% (with 95% CI of 0.025, 0.050).The prevalence of normal bite was higher in female 84% than male 77.7% where as male showed higher prevalence of deep bite 22.3% than female 16%.

Conflict of interest: None declared

References

1. Amin A., Rashid J.Z. Prevalence of deep bite in orthodontic patients in Sulaimani city ACross sectional Study.2015; 14(8):56-58

2. Upadhyay M., Nanda R. Etiology, Diagnosis, and Treatment of Deep Overbite. In: Nanda R,Kapila S.

- Current Therapy in Orthodontics Mosby Elsevier; 2010. P 186-198.
3. Mohamed Abuelazayem, SayedHafez, FoadSharaby. Prevalence and severity of anteriordeep bite in a sample of orthodontic patients. Aust. J. Basic & Appl. Sci.2014; 8(15):237-244.
 4. Parker CD., Nanda RS., Currier GF. Skeletal and dental changes associated with the treatment of deep bite malocclusion. Am J Orthod Dentofac Orthop. 1995; 107(4):382-93.
 5. Baratam S, Deep overbite-A review (Deep bite, Deep overbite, Excessive overbite). Annals Dent. 2009; 1(1):8-25.
 6. Proffit WR., Fields HW. Contemporary orthodontics. St Louis: C.V. Mosby; 2007.
 7. Fattahi H., Pakshir H., Beghdadabadi A.N., Jahrimi S. Skeletal and Dentoalveolar Features in Patients with Deep Overbite Malocclusion. Journal of Dentistry, Tehran University of Medical Sciences, Tehran, Iran 2014; 11(6):629-638
 8. Baydas B., Yavuz I., Atasaral N., Ceylan I., Dagsuyu I. Investigation of the changes in the positions of upper and lower incisors, overjets, overbite, and irregularity index in subjects with different depths of curve of Spee. Angle Orthod. 2004 J; 74(3):349-55.
 9. El-Dawlatly MM., Fayed MM., Mostafa YA. Deep overbite malocclusion: analysis of the underlying components. Am J Orthod Dentofacial Orthop. 2012; 7a 2(4):473-80.
 10. World Health Organization 1985 Oral health care systems. An international collaborative study. WHO, Geneva.
 11. Meer Z., Sadatullah S., Wahab A.M., Mustafa B.A., Odusanya A.S., Razak A.P. Prevalence of malocclusion and its common traits in Saudi males of Aseer region. J Dent Res Rev 2016; 3:99-102.
 12. Al-Hummayani FM. Incisor overbite in Saudi Arabia. Egypt Dent J 2005; 51:1-5,
 13. Erum G., Fida M. Pattern of malocclusion in orthodontic patients a hospital based study. Jayubmed collabbottabad 2008; 20 : 43-7 .
 14. Naeem S., Asaad S., Hamid MU. Prevalence of deep bite in orthodontic patients. Pakistan oral & dental journal 2008; 28: 181-82.
 15. Gabris R., Marton S., Malenda M. Prevalence of malocclusion in Hungarian adolescents. Eur J Orthod. 2006; 28: 467 -70.
 16. Celikoglu M., Akpınar S., Yavuz I. The pattern of malocclusion in a sample of orthodontic patients from Turkey. Med Oral Patol Oral Cir Bucal 2010; 15:791-6.
 17. Helm S. Malocclusion in Danish children with adolescent dentition: an epidemiologic study. Am J Orthod. 1968; 54: 356-66.
 18. Sassouni V., Nanda S. Analysis of dentofacial vertical proportions. Am J Orthod., 1964; 50: 801-20.
 19. Goyal S., Goyal S. Pattern of dental malocclusion in orthodontic patients in Rwanda- a retrospective hospital based study. Rwanda Medical Journal. 2012; 69 (4)
 20. Muppa R., Bhupathiraju P., Duddu MK., Dandampally A., Karre DL. Prevalence and determinant factors of malocclusion in population with special needs in South India. J Indian Soc Pedod Prev Dent 2013; 31:87-90.
 21. Vibhute AH., Vibhute NA., Daule R. Prevalence of malocclusion characteristics and chief motivational factor for treatment in orthodontic patients from Maharashtra, India. J Orthod Res 2013; 1:62-5.
 22. Oliveira AC., Paiva SM., Campos MR., Czeresnia D. Factors associated with malocclusions in children and adolescents with Down syndrome. Am J Orthod Dentofacial Orthop. 2008; 133-489