

Identification of Taenia from child of 6 year old

Sah R, Khadka S, Sherchand JB, Tandukar S, Bhandari D, Shrestha L*, Rijal B, Pokharel BM

Tribhuvan University Institute of Medicine, Department of Microbiology and Public Health Research Laboratory;

*Department of Child Health

Introduction:

Taeniasis is primarily a food-borne disease that spreads due to ingestion of improperly cooked pork or beef meat contaminated with the ova of *Taenia* spp. The meat (muscles) contains the cysticercii larva of *Taenia*. Once inside the human intestine larva in the meat develops into adult worm under favorable condition. Generally one patient harbors a single adult worm, which normally takes about 2-3 months to develop into a fully mature form from the larval stage. The gravid proglottids are then are passed in the stool along with the eggs^{1,2}.

Both the species of taenia (*T. saginata* and *T. solium*) cause taeniasis i.e., intestinal manifestation which include mild abdominal pain, decreased appetite or sometimes the patient remains asymptomatic. The intestinal symptoms is more severe in *T. saginata* as compared to *T. solium* but *Taenia solium* however can produce cysticercosis (neurocysticercosis, ocular cysticercosis) in the course of time, a clinical condition caused due to consumption of cysticercii larvae/ taenia eggs in a similar manner as that by a pig. Infestation of eggs occurs as a result of consumption of contaminated food, water and vegetables or through autoinfection.

Case Report:

A 6 Year old female child from Taplejung accompanied by her mother presented to Microbiology Department of Tribhuvan University Teaching Hospital (TUTH) (September 6, 2015) with the chief complain of intermittent passage of whitish chunk resembling a flat worm segment in her stool, since last 8 months. Prior to her reporting in TUTH (4 months earlier), she was under medication of a single dose of albendazoles prescribed by a local medical practitioner. She has history of consumption of a local cuisine prepared of buffalo meat- Dumpling (momo). She shows a healthy appetite with no other complains. Upon physical examination; she is an active and healthy looking child with no palpable nodules detected in her body. Following the initial complains and the results of laboratory investigations, she was prescribed praziquantel

at 15mg/kg stat dose. The patient was then asked to send stool samples for next 3 consecutive days in order to investigate the complete passage of proglottid segment and the head of tape worm.

Investigations:

Following investigations were done with the following results: 1, Peripheral blood: microcytic hypochromic and mild eosinophilia. 2, Stool examination by macroscopy found Immature *Taeniaproglottids*. Head of taenia was screened for in the 3 consecutive days stool sample but was not detected¹. 3, Microscopy : The stool sample was processed by direct smear technique in wet mount suspension for ova detection and acid fast staining for the species differentiation following the formal- ether concentration technique^{1,2} Figure 2 and 3.

The morphology and dimension of the stained ova was then observed/measured using cell sensation software attached to the BX3 Olympus camera used for microscopy. Control : two other samples positive for taenia eggs were used, one sample showed acid fast eggs (purplish red) the other showed negative staining (bluish colour) Figure 2 and 3 respectively

Size of the eggs : >35micrometer³ (Fig -4) as shown in table 1 and histological description (Table -1) and 3,4. Proglottids were washed to eliminate the excess of formalin and then passed through increasing ethanol concentrations (70°, 80°, 90°, and 100°) and then three times in xylol. Proglottid samples were then placed in paraffin blocks, sliced in 6 um sections, deparaffined, and placed on microscopy slides with polyllysine for staining. They were stained with haematoxylin and eosin stain (Figure 5), Eosin staining: Eosin staining of the proglottids showed eggs inside it which was similar to those detected in concentrated stool samples. Figure 5a, 5b and 6.

1. Ophthalmoscopic examination: no cysticerci seen.

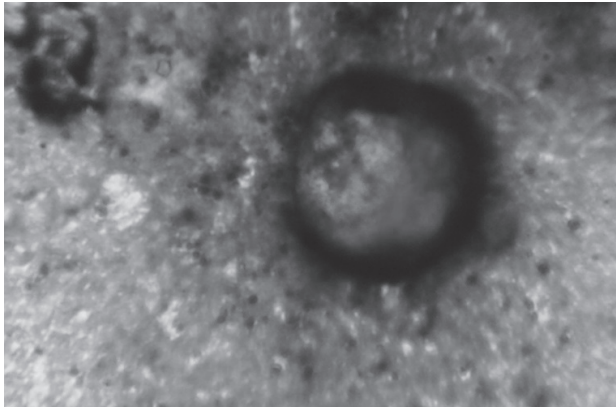


Figure1

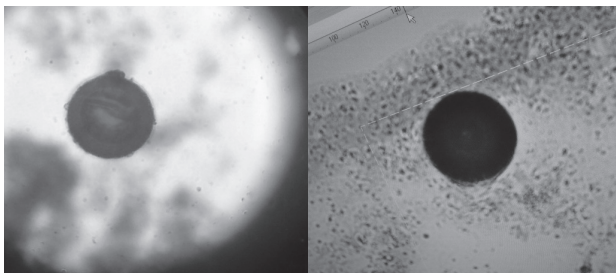


Figure 2 and 3




Figure 4.

Criteria	Species	Sensitivity	Specificity	Youden's J
Entirely magenta	T. saginata	54% (7/13)	96% (17/18)	0.50
Entirely blue/purple	T. solium	50% (4/8)	100% (13/13)	0.50
Ovoid	T. saginata	100% (13/13)	83% (15/18)	0.83
Spheric	T. solium	83% (15/18)	100% (13/13)	0.83
> 35 µm	T. saginata	100% (13/13)	100% (18/18)	1.00
< 35 µm	T. solium	100% (18/18)	100% (13/13)	1.00

Table -1³

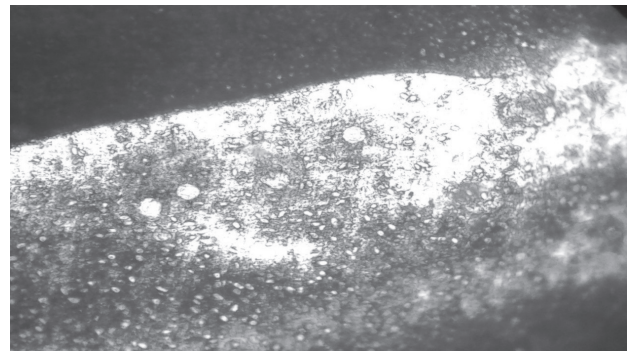


Figure-5a ova of taenia (blue arrow) under high power field inside the proglottid on eosin staining

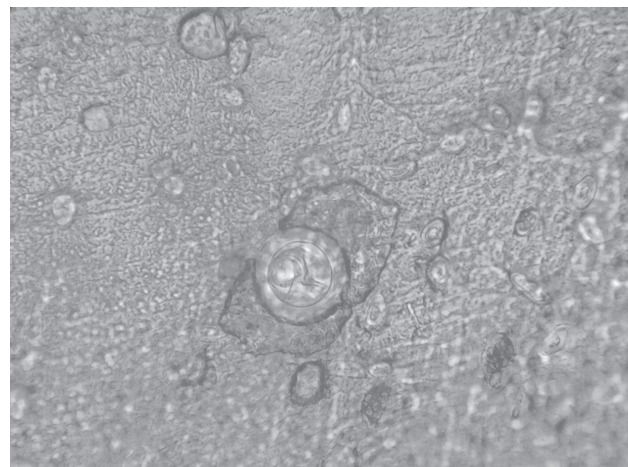


Figure 5 b.

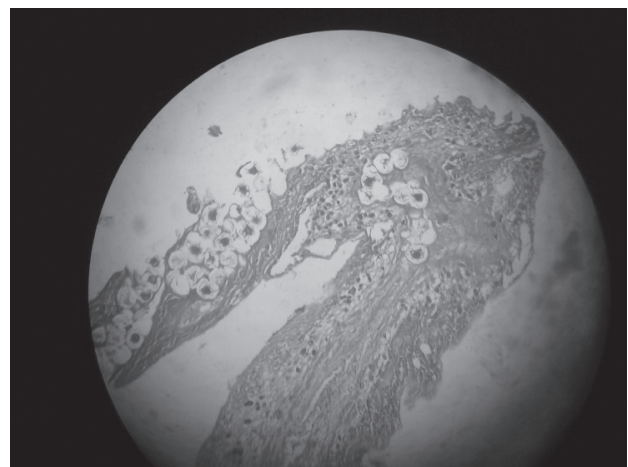


Figure 6: Haematoxylin and eosin staining of the taenia segment found in the stool of the patient.

Discussion:

ZN staining helps in differentiating the species as *Taenia solium* or *T. saginata*. The ova of *Taenia Saginata* are acid fast where as that of *Taenia solium* are not. Acid fast staining technique has been of high utility in species differentiation of taenia with the sensitivity of about 56% and specificity of about 96%. Studies have shown that size of more than 35 micrometer have 100% sensitivity and specificity to *Taenia saginata* eggs³.

Correct identification of the *Taenia* species is important because the consequences of human infection by the two parasites are different. *T. saginata* is relatively innocuous, since only the intestinal tapeworm phase occurs in man, whereas infection with *T. solium* has a major health effects due to extra intestinal infection by the larva in the CNS, eye producing neurocysticercosis, ocular cysticercosis respectively⁵. Neurocysticercosis occurs when cysts formed by the infection grow within the brain causing neurologic syndromes such as epileptic seizures. Neurocysticercosis most commonly involves the cerebral cortex followed by cerebellum. Pituitary is very rarely involved and involvement of the pituitary may result in multiple pituitary hormone deficiency.

Ocular cysticercosis may affect almost all eye tissues⁵. The vitreous cavity, subretinal space, and subconjunctival space are common sites, while involvement of other regions (eg, extra ocular muscles, optic nerve) is relatively less common. While either eye may be affected, bilateral involvement is rare. Multiple cysts may develop in the same eye⁶⁻⁸.

Ocular manifestations may be devastating as the cysticercus enlarges. The cysticercus may lead to blindness in 3-5 years. Decreased vision, pain, and recurrent redness of the involved eye are common symptoms of intraocular cysticercosis⁹.

The cyst usually presents in the subretinal space or vitreous cavity, where it can be observed ophthalmoscopically. The cyst appears as a well-defined translucent mass with a dense white spot (scolex) at one region. The site of entry into the eye is most probably the choroidal vasculature, from which the cyst migrates into the subretinal space, bores a hole in the retina, and enters the vitreous cavity. They produce uveitis, iridocyclitis, and secondary glaucoma. Intraocular inflammation may also cause cataract formation and iris atrophy. Subconjunctival cysticercosis usually presents as

a painful, yellowish, nodular subconjunctival mass with surrounding conjunctival congestion.

So a simple, easy and cheap test of ZN staining may be able to oblige the need of CT scan, fund oscopy reducing the economic burden on the patient and also prevents the devastating complications. By identification of the species of *T. solium*, the disease can be diagnosed early before the symptom appears thus preventing the complications.

Conclusion: *Taenia saginata* was identified in our patient by ZN staining and size measurement of the eggs.

References:

1. Parasitology thirteenth edition K.D Chatterjee
2. CKJ Paniker Text book of Medical Parasitology
3. Juan A. Jimenez, Silvia Rodriguez, Luz M. Moyano, Yesenia Castillo, and Héctor H. García Differentiating *Taenia* eggs found in human stools - Does Ziehl-Neelsen staining help? Trop Med Int Health. 2010 Sep; 15(9): 1077-1081.
4. Capron A, Rose F. [On the composition of helminth eggs. II. Alcohol-acid-resistance in cestodes. Difference of Ziehlstainability of embryophores of *Taenia saginata* and *Taenia solium*] Bull Soc Pathol Exot Filiales. 1962; 55:765-767. [PubMed]
5. Chapin K, Lauderdale TL. Reagents, stains, and media: bacteriology. In: Murray PR, Baron EJ, Jorgensen JH, Landr ML, Pfaller MA, editors. Manual of Clinical Microbiology. 9th ed American Society for Microbiology; Washington, D.C: 2007. p. 344.
6. Clavel A, Varea M, Doiz O, et al. Visualization of hydatid elements: comparison of several techniques. Journal of Clinical Microbiology. 1999; 37:1561-1563. [PMC free article] [PubMed]
7. Garcia HH, Del Brutto OH. Neurocysticercosis: updated concepts about an old disease. Lancet Neurology. 2005; 4:653-661. [PubMed]
8. Luna LG, editor. Manual of Histologic Staining Methods of the Armed Forces Institute of Pathology. 3rd Ed McGraw-Hill; New York: 1968. p. 28.
9. Verster A. A taxonomic revision of the genus *Taenia* Linnaeus, 1758 s. str. Onderstepoort Journal of Veterinary Research. 1969; 36:3-58. [PubMed]