

## Use of reverse sural artery flap for reconstruction of defects of distal leg, ankle and foot

Shrestha JM, Rayamajhi S, Lohani I, Manandhar K, Sharma S

Department of Plastic Surgery and Burns, Institute of Medicine, Tribhuvan University Teaching Hospital, Maharajgunj, Kathmandu, Nepal

**Corresponding author:** Dr Jayan Man Shrestha

**Emails:** jayanshrestha11@yahoo.com

### Abstract

**Introduction:** Reverse sural artery flap has been used effectively to cover defects of distal leg, ankle and foot. This flap is easier and quick to harvest and is a versatile flap in terms of extensive mobility and reliable vascularity and, in many instances it has obviated the need for free tissue transfer.

**Methods:** This is a retrospective study of sural flaps done at the Department of Plastic Surgery and Burns in Tribhuvan University Teaching Hospital over a period of 4 years from April 2011 to March 2015. It included 21 flaps carried out in 21 patients with soft tissue defects at distal lower leg, ankle and foot.

**Results:** Among 21 patients, 10 were men and 11 were women with an average age of 41 years (17 – 81). Successful flap coverage was obtained in 16 cases out of 21 (76%) which included 10 cases of complete survival (48%) and 6 cases (28%) of marginal flap necrosis. Four cases (19%) had partial flap loss and one case (5%) lost flap completely.

**Conclusion:** we found that reverse sural artery flap has good reliability with low incidence of complications and is a versatile flap for the reconstruction of defects in distal leg, ankle and foot

**Key words:** sural flap, distal leg, ankle, foot, flap survival, flap necrosis, skin strip

### Introduction

Soft tissue defects in the distal leg, ankle and foot occur mainly due to trauma and infection and present difficult problem for coverage as there are inadequate local tissue available, poor circulation to the tissues and tight skin. Local flaps used to cover these areas are limited in number which comprised of medial planter flap, dorsalis pedis artery flap, lateral supramalleolar flap, anterior tibial artery flap and posterior tibial artery perforator flaps. However these flaps have many limitations that include limited arc of rotation, difficult dissection, unreliable vascularity and sacrificing major artery in already traumatized limb. Free flap, an ideal option in most of these situations is also limited by its long duration of operation and unavailability of suitable vessels in the injured limb. The reverse sural flap is an excellent option for coverage of these defects. This flap

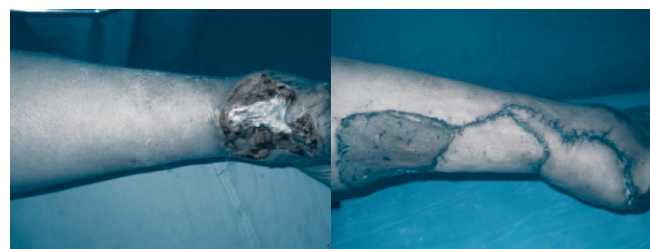
was first described by Masquelet et al<sup>1</sup> in 1992 as a neurocutaneous island flap as it was found to be supplied by arteries accompanying the sural nerve. Blood supply of the sural flap is sural arteries branches of which supply posterior part of the middle 1/3 of the calf skin. It anastomoses with the septocutaneous perforators of the peroneal artery in the distal 1/3 of the calf and that forms the basis of reverse flow of arterial supply to the sural flap. Peroneal septocutaneous perforators are quite constant in number and the most distal one is found at a distance of 4-5 cm above the tip of lateral malleolus and this point is taken as the pivot point of the flap. Main advantages of this flap are an extensive mobility and versatility, reliable vascularity without sacrificing important arteries. Objective of this paper is to present our experience of use of this flap in various defects of distal leg, ankle and foot.

**Methods:** This is a retrospective study of sural flaps done at the Department of Plastic Surgery and Burns in Tribhuvan University Teaching Hospital over period of 4 years from April 2011 to March 2015. It included 21 flaps carried out in 21 patients with soft tissue defects at distal lower leg, ankle and foot. Preoperatively the age and sex of each patient, etiology, site of the defect, co-morbid conditions like Diabetes Melitus, Hypertension were recorded. All patients underwent serial debridement before undertaking closure with sural flap. Peroneal perforators were identified by using handy Doppler and marked preoperatively especially in those cases with distal wounds and heel defects.

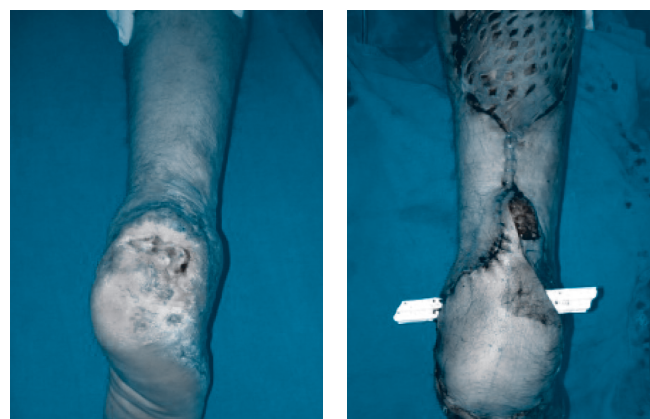
**Surgical technique:** Patients were positioned prone or lateral and a tourniquet was placed in the proximal lower limb. The recipient wound was prepared by debridement. The sural flap was outlined on the posterior aspect of middle one third of the leg according to the size of the recipient defect. More proximal extension of flap was carried out in case of defects over heel or dorsum of foot. The pedicle was drawn along a line from the popliteal fossa to the point midway between Achilles tendon and lateral malleolus. It extended from the distal margin of flap to the pivotal point of the pedicle ie 4-5cm above the lateral malleolus. About 1- 1.5cm of skin strip was included along the whole length of the pedicle in majority of cases. Thus the pedicle consists of skin, subcutaneous tissue, deep fascia, the small saphenous vein, the sural nerve and sural arteries. Skin incision was started at proximal flap margin and subdermal layer was dissected to expose the sural nerve, accompanying sural vessels and short saphenous vein. The saphenous vein and the sural nerve were ligated at the proximal border of the flap. The proximal, lateral and medial border of the flap were incised down to the muscle and the flap raised. The pedicle with width of 3-4 cm subcutaneous tissue and fascia was elevated. Tourniquet was deflated and adequate circulation of the flap was verified. The flap was left over for 3-5 min in an outstretched position or covered with warm saline soaked gauze to increase the flap circulation. The flap was then transferred to the recipient site by opening the skin bridge to the defect. The donor defect was covered with split thickness skin graft. The skin margins at the pedicle harvest site proximal to the pivot point were sutured directly. The tension is unlikely at this closure site even after including the skin strip as there is also simultaneous removal of underlying wide adipofascial tissue. The strip of skin overlying the pedicle is useful to cover the soft tissues of the region between pivotal point and the recipient

site. It can cover the soft tissue completely (Figure 1) if the tissues are lax or should cover it partially only if there is likelihood of tension at this site.(Figure 2) In case of partial cover the raw area over the pedicle was skin grafted. In some cases a 2 cm wide skin paddle over pedicle site was elevated along with the flap and the pedicle harvest site was skin grafted as could not be closed primarily.(Figure 3) Similarly in few cases, islanded sural flap was harvested and pedicle harvest site was closed primarily and pedicle itself skin grafted. (Figure 4) The flap was sutured loosely applying few sutures without any tension. Drains were inserted under the flap. The limb was dressed with gauze and cotton padding and bandaged leaving a window to inspect the flap at regular intervals. The limb was elevated with care to prevent any compression over the pedicle and grafted areaa.

Postoperatively the flap was monitored for any venous congestion or pallor. Outcome measures were flap viability in terms of complete or partial flap survival, recipient defect coverage, ease or difficulty in walking or wearing shoes, loss of sensibility in the sural distribution area, any concerns of the patient regarding the aesthetic appearance of the flap.

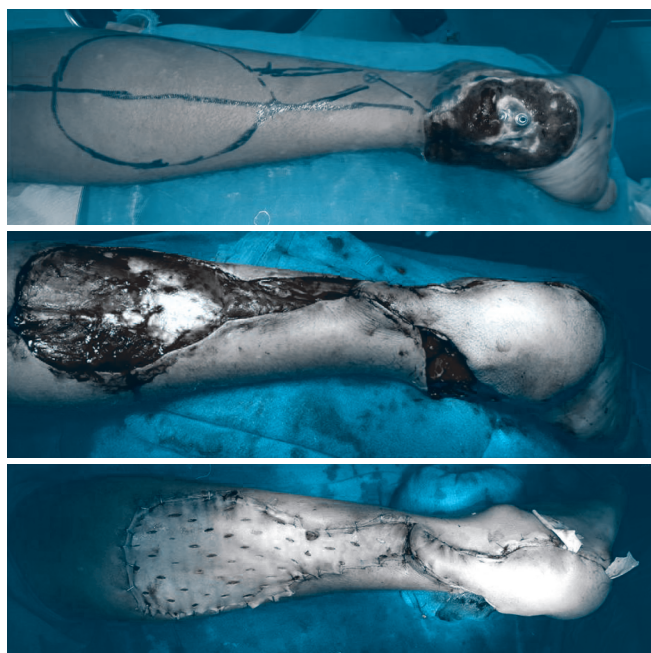


**Figure 1: Sural flap with 1 cm strip of skin harvest. Pedicle harvest site was closed primarily and the skin strip used to cover defect completely.**

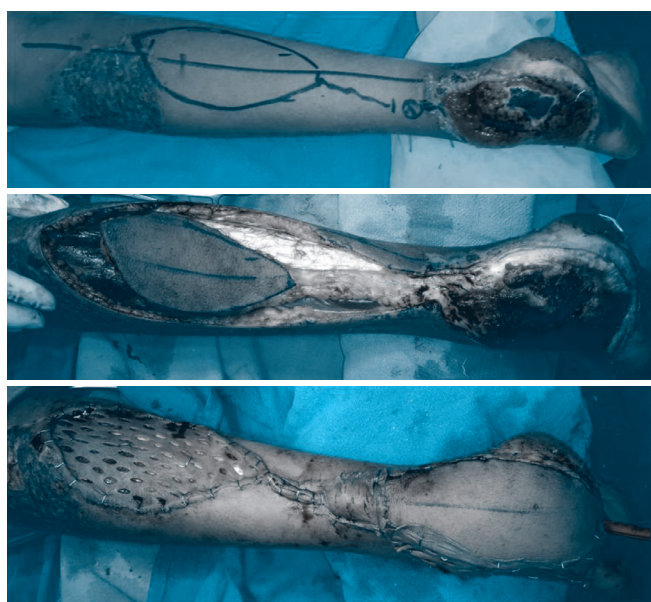


**Figure 2: Sural flap with 1 cm strip of skin harvest. Pedicle harvest site was closed primarily and the skin strip used to cover defect partially only, and remaining raw area grafted.**





**Figure 3: Sural flap with 2 cm wide skin paddle over pedicle. Pedicle harvest site was closed with skin grafting.**



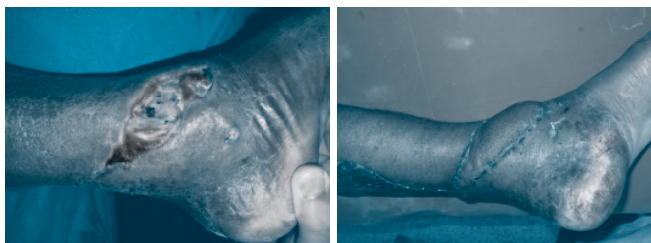**Figure 4: Islanded sural flap harvest. Pedicle harvest site was closed primarily and pedicle was skin grafted.**

## Results

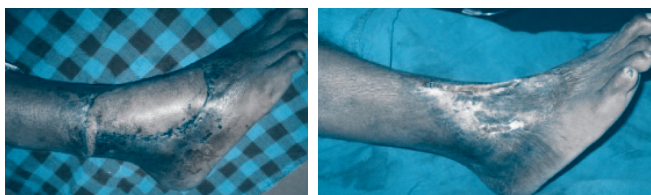
The patients comprised of 10 men and 11 women with an average age of 41 years (17 – 81). The soft tissue defect in the lower limbs in this study was located on the heel and posterior aspect of foot in 8 cases (38%), on ankle and malleolar areas in 7 cases (33%) (Figure 5), on the distal leg in 4 cases (19%) and dorsum of foot in 2 cases

(10%) (Figure 6). Of the 8 cases of heel defects, 5 cases were on the posterior non weight bearing area whereas 3 cases involved anterior weight bearing area. Thirteen out of 21 patients (62%) had sustained injury in road traffic accidents. Three patients (14%) had wound defect after skin infection and 3 patients (14%) had diabetic foot. Two patients (10%) had sustained burn injury over distal leg and foot. Dorsalis pedis and posterior tibial artery pulses were present in all patients. Most of the flaps (14 out of 21 cases) were designed in the middle third of the leg, whereas seven flaps comprised of flaps extended to proximal leg. In 15 cases, 1-1.5 cm of skin strip over the pedicle was also harvested along with the sural flap. In 3 cases, 2 cm wide skin paddle over the pedicle was harvested and in another 3 cases, islanded sural flap was harvested. The pivot point was kept 5-6 cm proximal to the lateral malleolus in most cases. Handy Doppler was used to identify peroneal perforators in 10 cases that made more distal dissection towards perforator easier and helped to shift pivot point more distally. Most of the defects could be covered with sural flap only and six cases required skin grafting besides sural flap to cover the remaining raw areas.

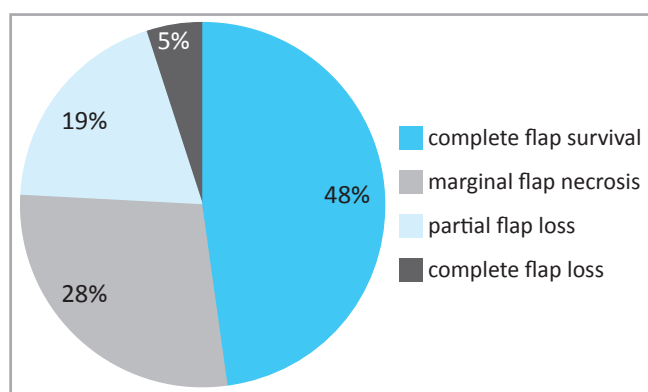
Out of 21 cases, 10 sural flaps (48%) survived completely and did not require any secondary procedure. Six cases (28%) had developed marginal flap necrosis. (Figure 7) These were treated with debridement and closure with advancement of flap or secondary healing. In four cases (19%) there was partial flap loss which was between one fourth to one third of the flap dimension.. Location of defects in patients with partial flap loss was heels (2 cases) and distal dorsum foot (1 case). The necrosed flap was removed and dressing was done till wound was clean. In 2 out of 4 partial flap loss cases, the wound defect was covered with skin grafting whereas in another 2 cases, the defect was closed with local flap. There was a single case (5%) of complete flap loss who was an 81 years elderly and expired 1 week after the surgery due to cardiac cause. All patients had loss of sensation on lateral side of foot on sural nerve distribution area but no botheration or paresthesia noted in those areas. Non of them complained about disfigurement of the donor site but 2 patients had difficulty in wearing shoes due to bulkiness of the flap which were later subsided significantly with application of compression bandages and stockinet.



**Figure 5: Sural flap cover of defect on ankle and medial malleolar region.**



**Figure 6 : Sural flap cover of defect over ankle and dorsum of foot**



**Figure 7: Distribution of cases showing sural flap viability. Successful coverage in 16 cases (76%) that includes complete survival and marginal flap necrosis cases.**

## Discussion

The sural flap constitutes a reliable and versatile technique to cover the difficult regions of the lower limb ie. distal leg, ankle, heel and dorsum of foot. After the discovery of this flap in 1992 by Masquelet et al<sup>1</sup>, its usefulness was widely accepted and is being commonly used all over the world for the coverage of wounds over these areas. The sural flap that we used in our series has many advantages which are as follows - the simplicity of the design and dissection of the flap, the preservation of the major vessels of the lower limb and need for only one operation. The other advantages are short operative time, wide rotation arc, acceptable donor site morbidity and possibility of relatively large flap harvest.

Road traffic accident (62%) was found to be the commonest cause of distal leg and foot defects in our patients, followed by diabetic foot and post infective wounds. The causes of these defects reported in the literature include those resulting from road traffic accidents, non healing skin wounds, chronic venous ulcers, chronic osteomyelitis in diabetics, contractures, unstable scars, cancer resections, electrical burns, exposed hardware.<sup>1-5</sup> Akhtar S<sup>3</sup> reported road traffic accident as the cause of these defects in 63% of the cases whereas Dhamangaonkar AC<sup>5</sup> and Olawoye OA<sup>6</sup> mentioned 56% and 95% respectively for this cause.

We noted successful flap coverage in 76% of cases that includes 48% of complete flap survival and, 28% of marginal skin necrosis. Lack of arterial supply was the cause for the marginal necrosis in 4 cases out of six whereas another 2 cases of marginal necrosis was due to venous congestion. There was partial flap loss in 4 cases (19%) and three of these had developed venous congestion which was treated with removal of tight sutures near the pedicle. Different studies have shown that venous congestion, and not lack of arterial supply, is the most common cause of flap necrosis.<sup>7</sup> The main reason of venous congestion is the presence of venous valves that can prevent the retrograde flow of blood out of the flap even though reverse flow is said to occur through bridging vena commitants that bypass the venous valves. The techniques to improve venous outflow are exteriorising the pedicle<sup>8</sup>, intermittent drainage of short saphenous vein<sup>9</sup>, leaches, and the supercharging of the flap by anastomosing the proximal end of the lesser saphenous vein to a vein in the recipient defect<sup>10</sup>. Total flap loss occurred in one case who had peripheral vascular disease and did not have adequate perfusion intraoperatively.

Akhtar S<sup>3</sup> in his study of 84 patients observed similar result of flap survival (78.5%) as in our study (76%). Partial necrosis occurred in 16.5% of cases mostly involving heel and dorsum of foot defects that are similar to our results (19%). A meta-analysis of 50 articles that report the use of 720 distally based sural flaps, suggested 82% success rate of the flap. Complete flap necrosis was reported in 3.3%, and partial or marginal flap necrosis in 11%.<sup>11</sup>

The heel and dorsum of foot are areas which are difficult to reach by conventional techniques of flap harvest. We designed flap more towards proximal leg in these cases and also used handy Doppler to exactly localize the perforator and dissect as far as distal down to the



perforator for further distalisation of pivot point of the flap. Different authors had successfully treated distal wounds of the sole and foot with the extended flaps to the proximal third of leg.<sup>12-15</sup> They had included various modifications to increase blood supply to the sural flap which are larger pedicle width, delay procedure, use of gastrocnemius muscle cuff in higher flap design.<sup>16-21</sup> Samira A reported 88% of successful flap coverage, 8% partial flap loss and 4% complete loss in their studies and stated that complete survival of flaps used for anterior heel or dorsum of foot defects observed in their results were because of use of these modifications to the sural flap.

Olawoye OA<sup>6</sup> reported satisfactory flap healing in 85% cases and Dhamangaonkar AC<sup>5</sup> reported uneventful flap healing in 89.21%. Bista N<sup>4</sup> performed 11 sural flaps to cover defects in ankle, heel and dorsum of hind and mid foot and resulted flap viability in 10 cases (91%). Cheema SA<sup>14</sup> utilized sural flap with various modifications in 66 cases and resulted into successful flap in 62 cases (94%). Similarly Ignatiadis IA<sup>22</sup> achieved flap viability in 15 out of 16 cases (94%). Pan HT<sup>15</sup> and Kt R<sup>13</sup> used sural flaps extended to proximal third of leg and reported 100% successful flaps in their studies. Tsai J<sup>23</sup> reported success of reverse sural flap from proximal part of posterior calf that included various modifications like designing 7 cm wide adipofascial pedicle with a 2 cm skin paddle, with or without including gastrocnemius muscle cuff, supercharging with lesser saphenous vein. All the flaps survived completely in their study.

## Conclusion

Reverse sural artery flap is a good option to cover defects of distal third leg, ankle, heel and dorsum of foot because of its constant and reliable arterial supply with excellent survivability of the flap. As the procedure of flap harvest itself is easier and quick, it is a versatile flap useful to cover these areas.

## Conflict of interest: None declared.

## Reference

- Masquelet AC, Romana MC, Wolt G. Skin island flaps supplied by the vascular axis of the sensitive superficial nerves: anatomic study and clinical experience in the leg. *Plast Reconstr Surg* 1992; 89: 1115-21.
- Mileto D<sup>1</sup>, Cotrufo S, Cuccia G, Delia G, Risitano G, Colonna MR, d'Alcontres FS. The distally based sural flap for lower leg reconstruction: versatility in patients with associated morbidity. *Ann Ital Chir.* 2007 Jul-Aug; 78 (4):323-7.
- Akhtar S, Hameed A. Versatility of the sural fasciocutaneous flap in the coverage of lower third leg and hind foot defects. *J Plast Reconstr Aesthet Surg.* 2006; 59(8):839-45. Epub 2006 Mar 9.
- Bista N, Shrestha KM, Bhattachan CL. The reverse sural fasciocutaneous flap for the coverage of soft tissue defect of lower extremities (distal 1/3 leg and foot). *Nepal Med Coll J.* 2013 Mar; 15(1):56-61.
- Dhamangaonkar AC, Patankar HS. Reverse sural fasciocutaneous flap with a cutaneous pedicle to cover distal lower limb soft tissue defects: experience of 109 clinical cases. *J Orthop Traumatol.* 2014 Sep; 15(3):225-9.
- Olawoye OA, Ademola SA, Iyem K, Michael A, Oluwatosin O. The reverse sural artery flap for the reconstruction of distal third of the leg and foot. *Int Wound J.* 2014 Apr; 11(2):210-4.
- Baumeister SP, Spierer R, Erdmann D et al. A realistic complication analysis of 70 sural artery flaps in a multimorbid patient group. *Plast Reconstr Surg* 2003; 112:129-40.
- Maffi TR., Knoetgen J, Turner NS, Moran SL. Enhancing survival using the distally based sural artery interpolation flap. *Ann Plast Surg* 2005; 54:302-5.
- Follmar KE, Baccarani A, Steffen P, Baumeister L, Levin S, Erdmann D. The distally based sural flap. *Plast Reconstr Surg* 2007; 119:138-48.
- Tan O, Atik B, Bekerecioglu M. Supercharged reverse-flow sural flap: a new modification increasing the reliability of the flap. *Microsurgery* 2005; 25: 36-43.
- Follmar KE, Baccarani A, Steffen P, Baumeister L, Levin S, Erdmann D. The distally based sural flap. *Plast Reconstr Surg* 2007; 119:138-48.
- Samira A et al. distally based sural fasciocutaneous flap for soft tissue reconstruction of the distal leg, ankle and foot defects. *J Ayub Med Coll Abbottabad* 2009; 21(4):19-23.
- Kt R, Mn P, M S. Extended Reverse Sural Artery Flap's Safety, Success and Efficacy - A Prospective Study. *J Clin Diagn Res.* 2014 May; 8(5):NC08-11.
- Cheema SA, Malik AL, Asim M. Role of reverse sural artery flap for soft tissue defects of lower limb: experience with 66 cases. *J Ayub Med Coll Abbottabad.* 2014 Oct-Dec; 26(4):423-7.
- Pan HT, Zheng QX, Yang SH, Wu B, Liu JX. Versatility of reverse sural fasciocutaneous flap for reconstruction of distal lower limb soft tissue defects. *J Huazhong Univ Sci Technolog Med Sci.* 2014 Jun; 34(3):382-86.

16. Chen SL, Chen TM, Wang HJ. The distally based sural fasciomusculocutaneous flap for foot reconstruction. *J Plast Reconstr Aesthet Surg* 2006; 59: 846–55.
17. Foran MP, Schreiber J, Christy MR, Goldberg NH, Silverman RP. The modified reverse sural artery flap for lower extremity reconstruction. *J Trauma* 2008; 64:139–43.
18. Tosun ZO, zkan A, Karacor Z, Savaci N. Delaying the reverse sural flap provides predictable results for complicated wounds in diabetic foot. *Ann Plast Surg* 2005; 55:169–73.
19. Ulrich MD, Bach, Alexander D, Polykandriotis E, Juergen K, Horsch RE. Delayed Flap for Staged Reconstruction of the Foot and Lower Leg. *Plast Reconstr Surg* 2005; 116:1910–7.
20. Al-Qattan MM. The reverse sural artery fasciomusculocutaneous flap for small lower-limb defects: the use of the gastrocnemius muscle cuff as a plug for small bony defects following debridement of infected/necrotic bone. *Ann Plast Surg* 2007; 59:307–10.
21. Al-Qattan MM. The reverse sural fasciomusculocutaneous "mega-high" flap: a study of 20 consecutive flaps for lower-limb reconstruction. *Ann Plast Surg* 2007; 58: 513–6.
22. Ignatiadis IA, Tsiampa VA, Galanakis SP, Georgakopoulos GD, Gerostathopoulos NE, Ionac M, Jiga LP, Polyzois VD. The reverse sural fasciocutaneous flap for the treatment of traumatic, infectious or diabetic foot and ankle wounds: A retrospective review of 16 patients. *Diabet Foot Ankle*. 2011; 2.
23. Tsai J, Liao HT, Wang PF, Chen CT, Lin CH. Increasing the success of reverse sural flap from proximal part of proximal calf for traumatic foot and ankle reconstruction: patient selection and surgical refinement. *Microsurgery*. 2013 Jul; 33(5):342-9.