

A Study of the relationship of structures at Mandibular Foramen”

Baral P¹, Bastola D², Shrestha RN³

1. Department of Anatomy, B.P Koirala Institute of Health Sciences, Dharan, Nepal.

2. Department of physiology, Institute of Medicine, Maharajgunj, Kathmandu, Nepal

3. Department of Anatomy, Institute of Medicine, Maharajgunj, Kathmandu, Nepal

Corresponding to: Dr. Prakash Baral, Associate professor, Department of Anatomy, B.P Koirala Institute of Health Sciences, Dharan, Nepal.

Email: prakashbaral2002@yahoo.com

Abstract

Introduction : Mandibular foramen is located on medial aspect of ramus of mandible. Inferior alveolar artery and nerve enters into the foramen and inferior alveolar vein comes out of it. Dissection studies on 16 male and 4 female cadavers suggested that inferior alveolar nerve was medial to inferior alveolar vessels and inferior alveolar artery was anterior to inferior alveolar vein. Knowledge of interrelationship of structures at mandibular foramen is important for dental surgeon or oral surgeons while giving the inferior alveolar nerve block.

Key words: mandibular foramen, inferior alveolar nerve, inferior alveolar artery.

Introduction

Mandibular foramen lies on the medial aspect of ramus of mandible that leads to the


inferior alveolar canal. Inferior alveolar nerve (IAN) and artery (IAA) enter into this canal and inferior alveolar vein (IAV) comes out of the canal through this foramen^{1,2}. The relationship of these structures passing through the mandibular foramen has not been established so far. Thus this study had been carried out with the aim to find out the relationship of structures at mandibular foramen.

Methods

Twenty male and eighteen female adult cadavers were dissected out in infratemporal region on both right and left side. The relationship of the structures at the mandibular foramen was noted on both right and left sides.

Results

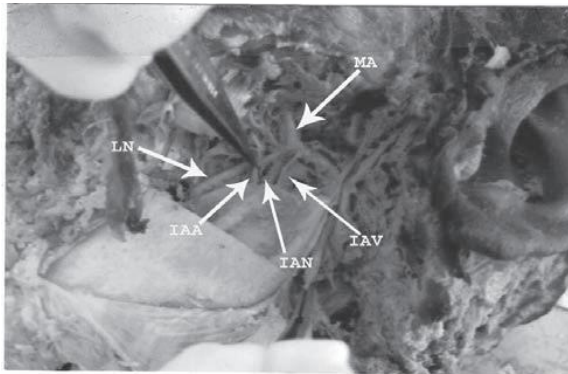
The inferior alveolar nerve lay anteromedial to inferior alveolar blood vessels; inferior alveolar artery was anterior to the vein in all cases (see fig.1 & 2 below).



Mandibular foramen fig.1:

Legends for fig.1

- LN- Lingual nerve
- IAA - Inferior alveolar artery
- IAV - Inferior alveolar vein-
- PVP - Pterygoid venous plexus



Mandibular foramen fig.2:

Legends for fig.2

- LN- Lingual nerve
- MA - Maxillary artery
- IAA - Inferior alveolar artery
- IAN - Inferior alveolar nerve
- IAV - Inferior alveolar vein

Clinical Significance

The dental or oral surgeons while extracting the mandibular posterior teeth and doing surgery in mandibular posterior regions need to give local anesthetic solution for inferior alveolar nerve block. Sometimes they may aspirate the blood and they have to change the direction of the syringe needle. They have to deposit the solution near the vicinity of the inferior alveolar nerve. Aspiration of the blood during local anesthesia for inferior alveolar nerve suggests that needle is inside the blood vessels i.e posterolateral to the inferior alveolar nerve. Thus they should change the direction of the needle anteromedially. In this way the knowledge of relationship of structures at mandibular foramina is very necessary for the dental surgeons.

Conflict of interest: None declared.

References

1. Romanes GJ. Cunningham's manual of practical anatomy. 15th ed. Oxford. Oxford university press, 2003; 127.
2. Standring S, Berkovitz BKB, Hackney Carole M, Raskell GL, Collins P, Wigley C. Head and Neck In: Ellis H, Healy JC, Johnson D, Williams A, Collins P et.al editors. Gray's Anatomy. 39th ed. Philadelphia: Elsevier Churchill Livingstone. 2005; 519-525.