

Disseminated Cysticercosis in a Child: A Rare Presentation

¹Poudel DR, Lhaden T, Shrestha M

Department of Pediatrics, Institute of Medicine, Maharajgunj Medical Campus

Correspondence: Dr Damanraj Poudel

Email: poudeldamanraj@hotmail.com

Abstract

We here present a rare case of disseminated cysticercosis presented with clouding of cornea with gradual loss of vision in the right eye and multiple nodules all over the body. Ophthalmologic evaluation revealed none perception of light on right eye with calcified cyst in entire intraocular lens. MRI of the brain showed starry sky pattern in brain parenchyma and multiple calcified cysts in the orbit. Serological test (ELISA) for cysticercal IgG antibodies was positive. Histopathology report on an excised biopsy from subcutaneous nodule also showed calcified cyst. She was treated initially with steroid for 3 days followed by albendazole for 2 weeks. MRI was repeated after 3 months which showed no resolution of the lesion. Later she presented with generalized seizure managed with anticonvulsant.

Keywords: cysticercosis , calcified cyst,

Introduction

Cysticercosis has been known as early as 1550. Even today, cysticercosis is a common public health problem especially in developing countries especially in South East Asia and of which neurocysticercosis (NCC) is the most common parasitic infestation of the central nervous system worldwide.¹

Human cysticercosis is caused by *Cysticercus cellulosae*, the larval form of the tapeworm *Taenia solium* and is disseminated from the intestine via the hepatportal system to the tissues of the organs of the body. Humans acquire through faeco-oral contamination with *Taenia solium* eggs from tape worm carriers. Cysts occur in the brain, striated muscles, ocular and subcutaneous tissue. Neurocysticercosis is the commonest presentation of human cysticercosis and is the most common cause of epilepsy and neurological morbidity in the developing country.² Disseminated cysticercosis is an uncommon manifestation involving other organs apart from the brain.³ The main clinical features of disseminated form include intractable epilepsy, dementia, enlargement of muscles, subcutaneous and lingual nodules and relative absence of focal neurological deficits or obviously raised intracranial pressure.⁴

Case: A 10 year old girl, from rural part of Nepal, presented with a history of multiple small swellings all over the body more on bilateral temporal region, upper limbs and lateral chest for the past one and half years and gradual, progressive loss of vision in the right eye for the past three months. There was no history of seizure, loss of consciousness or any change in behavior. There was also no history of recurrent fever, chronic cough, weight loss, decreased appetite or any history suggestive of bleeding disorder. History of eye discharge, red swollen eye and preceding trauma to the eyes were absent.

On general examination, she was found to be a well nourished individual. Her vital parameters were all within normal limits. Multiple, painless, firm, pea sized (3 x 5 mm), subcutaneous nodules were detected all over the body viz bilateral temporal, right medial lower arm (Figure 1) and right chest (axillary) regions. Her right eye revealed white pupillary reflex with none perception of light and on fundoscopy calcified cyst was seen occupying the entire intraocular lens (Figure 2).





Figure 1 Subcutaneous nodule, **Figure 2** White papillary reflex

Her neurological assessment was intact with no cranial nerves (except for vision acuity in the right eye), motor and sensory deficits. Rest of the systemic examinations was also normal.

Routine blood investigations including HIV serology were normal. MRI of Head and Orbit revealed multiple diffuse (parenchymal, intraventricular, cisternal space) calcified cysts with starry sky appearance (Figure 3). It also showed right intraocular cysticerci (along with evidence of retinal detachment) and in the posterior vitreous chamber (Figure 4). It showed multiple myocysticerci in the right medial rectus and bilateral masticator space muscles and longus colli muscle of left side of nasopharynx and also there were deposition in the left parotid gland. ELISA for cysticercal IgG antibodies was found to be positive (1:8 titre).

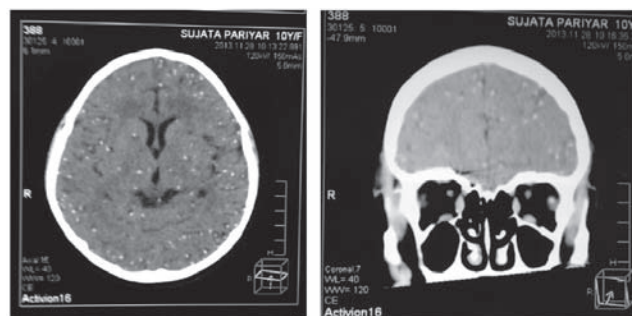
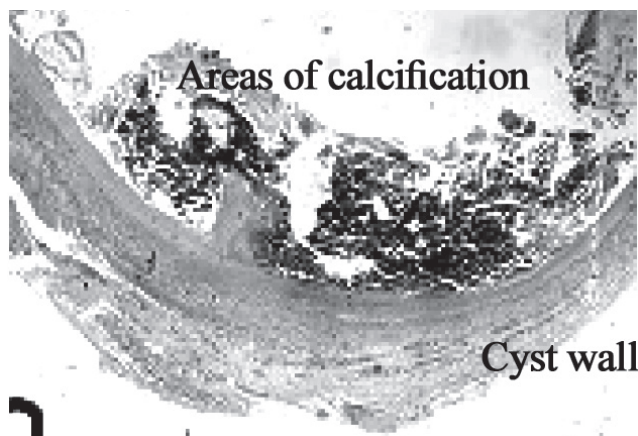


Figure 3 Calcified cysts in the cerebrum with starry appearance, **Figure 4**. Cysts in the posterior vitreous chamber

Histopathology report on an excised biopsy from subcutaneous nodule showed calcified cyst measuring 0.5x0.5cm probably cysticercosis.

A final diagnosis of disseminated cysticercosis was made and the patient was started with steroid (oral dexamethasone @0.15mg/kg/day) and with anti-cysticercal (oral albendazole @15mg/kg/day) of 28 days. MRI was repeated after three months, however there was no resolution of lesion. Later she had generalized seizure which was managed with anticonvulsant.



Her eye evaluation was done by the Ophthalmology Department and was advised for only non surgical management with the proper explanation to the patient's parents about the poor prognosis of her eye.

Discussion: Although cysticercosis is quite a common, disseminated cysticercosis (DCC) with multiple organ involvement is rather rare. So far only around fifty cases have been documented and among which the presentation in the children is the rarest. Puskher et al were probably the first to report a case of orbital cysticercosis associated with multiple cysts in the brain and the subcutaneous tissue in adults.¹⁰ To the best of our knowledge, this is the first case of DCC to be reported in Nepalese context. The diagnosis made in our case was based on the clinical presentations, presence of cystic lesion highly suggestive of neurocysticercosis on brain imaging, positive serum immunoassay for the detection of anticysticercal antibodies and histopathological finding of skin excisional biopsy.

Ashima Vaidya et al pointed out that the clinical features of disseminated cysticercosis depend on the localization of the cysts in the organs, parasitic burden and host parasitic interaction. The central nervous system is the most commonly involved in DCC followed by striated muscles, subcutaneous tissues and orbits¹ as we had seen in our case too. CT scan and MRI imaging are the useful in anatomical localization of the cysts. MRI being more sensitive than CT as it identifies scolex and live cysts and associated inflammation as mentioned by Lucato LT et al.⁶ Recently in 2010, Atin Kumar et al reported a pediatric symptomatic case of extensively disseminated cysticercosis which involved striated muscular system, subcutaneous tissues, paraspinal region, lungs, tongue and parotid glands which was diagnosed on the basis of whole body MRI with parallel imaging.⁷ Serological test for detecting antibodies against cysticercosis are used to confirm the diagnosis and has ~90% sensitivity and specificity.⁸

Management of disseminated cysticercosis is symptomatic (anti-epileptics and steroids), cysticidal and surgical (Removal of the cysts and putting VP shunt). The control of seizures with epileptic drugs is better after treatment with cysticidal drugs than when the disease is left untreated. Del Brutto et al found 83% of those who received cysticidal treatment became seizure free compared to only 26% of those who did not receive treatment.⁹ There is no role for cysticidal drugs in inactive neurocysticercosis i. e. calcified cysts since the parasites are dead. As mentioned by Ruth Ann et al, antiepileptic therapy may also be appropriate for patients who do not present with seizures but who are at high risk for seizures. The risk of seizures appears to be highest in the setting of multiple lesions, particularly when the lesions are degenerating and are surrounded by inflammation. Calcified, inactive lesions can also serve as foci for seizures but, in an otherwise asymptomatic patient, are not generally considered an indication for prophylactic antiepileptic drug therapy¹⁰. Prophylactic antiepileptic could have been started in our case because of multiple lesions even though she had no history of seizure at the initial presentation.

Ocular cysticercosis was managed conservatively in our case as cyst was completely calcified in intraocular lens and chance of improvement in vision was negligible. As mentioned, the management of ocular cysticercosis is essentially a surgical disease and the outcome is not usually good and enucleation is frequently required.⁸

Conflict of interest: None declared.

References

1. Vaidya A et al. Asymptomatic Disseminated Cysticercosis. *Journal of Clinical and Diagnostic Research*. Aug 2013 , vol-7(8): 1761-1763
2. Bhalla A et al. Disseminated Cysticercosis: A case report and review of literature. *Journal of Medical case reports*. April 2008 , 2: 137
3. Kumar A et al. Disseminated Cysticercosis; Case Reports, *Indian Pediatrics*. April 1996 vol 33: 337-339
4. Devi S et al. A rare case of disseminated cysticercosis, *Neurology Asia* 2007; 12: 127-130
5. Pushker N et al .Disseminated Cysticercosis involving orbit, brain and subcutaneous tissue. *J Infection* 2005; 51(5):e245
6. Lucato LT et al. The role of conventional MRI sequences in the evaluation of NCC: impact on characterisation of the scolex and lesion burden. *am J Neuroradio* 2007;28(8);1501-1502
7. Kumar A et al, Disseminated cysticercosis in a child: whole body MR Diagnosis with the use of parallel imaging: *PediatricsRadiology*.2010;40;223-27
8. Ronald Blanton. Cysticercosis. In Kliegman RM, Stanton BF, ST. Geme, Schor NF, Behrman RE. *Nelson textbook of pediatrics* 2012, 19th Edition Vol 1(295):1234-1236
9. Del Brutto OH .Neurocysticercosis.. *Semin Neurology* 2005;25(3):243-251
10. Ruth Ann Baird, Sam Wiebe, Joseph R. Zunt, et al. Evidence-based guideline: Treatment of parenchymal neurocysticercosis: Report of the Guideline Development Subcommittee of the American Academy of Neurology. *Neurology* 2013;80;1424-1429.

