

# Warthin's tumor of Submandibular gland

P. Adhikari, B. K. Sinha, D. K. Baskota

Department of ENT and Head and Neck Surgery, TU Teaching Hospital, Kathmandu, Nepal.

**Correspondence to:** Dr. Prakash Adhikari, Department of ENT and Head and Neck Surgery, TU Teaching Hospital, Kathmandu, Nepal.

e-mail: prakash\_ooz@hotmail.com

## Abstract

Warthin's tumour is a benign tumour which is exceedingly rare in submandibular gland. Here, we report a case of warthin's tumour of submandibular gland in a 64 years old female which is treated with excision of tumour along with the gland. A brief review of literature is also included.

**Key words:** Submandibular gland, warthin's tumour, cyst-adenolymphoma

## Introduction

Although parotid gland is the preferred localization for warthin's tumour (cyst-adenolymphoma), extraparotid Warthin's tumor has also been described frequently.<sup>1</sup> It is a benign tumor of the parotid gland and constitutes approximately 6 to 14% of all parotid gland neoplasms.<sup>2</sup> Its macroscopic aspect is that of a well defined, encapsulated tumour while histology of this tumour consists of two parts. The epithelial portion is formed by oncocytes where as the nonepithelial part presents itself as stroma interspersed with lymph follicles.<sup>1</sup> Malignant transformation of Warthin's tumour is extremely rare.<sup>3</sup> Treatment of choice is complete excision. It is note-worthy that the tumor occurs in sixth and seventh decade of life, more frequently in smokers and has a male predominance.

## Case Report

A 64 years old female presented to the Department of ENT-Head and Neck Surgery, TU Teaching Hospital with a painless, slowly progressing swelling in the right submandibular region. On examination it was a 3 x 2 cm well defined, firm, nontender, smooth, nonfluctuant, mobile and bimanually palpable swelling in the right submandibular region (Figure: 1). Other ENT and Head and Neck examination and systemic examination were normal. Fine needle aspiration of the swelling revealed it to be Warthin's tumour. The tumor was completely excision along with the gland.

Histology showed an encapsulated tumor mass consisting of predominantly cystic and solid areas, composed of epithelial and lymphoid components. There were papillary structures projecting into the lumina having fibrovascular cores with lymphoid stroma. There were oncocytic luminal cells and basal layer cells and cystic spaces contain eosinophilic secretion with formation of crystals (Figure: 2). These findings were consistent with Warthin's tumor and confirmed the diagnosis. Postoperative period was uneventful.

## Discussion

Cystadenolymphoma was first described by Albrecht and Arzt as a separate diagnostic entity which they named 'papillary cyst adenomas' in lymphatic glands.<sup>5</sup> Warthin reported a few patients with such tumors and initiated the study of this tumour in the English speaking countries where it became popularized as Warthin's tumour.<sup>6</sup>

Although it is predominally a tumour of the parotid gland, a small percentage of the tumor may arise in other minor salivary glands of the oral cavity, tongue, oropharynx, nasal cavity and maxillary sinus.<sup>7</sup> It is more common in males and the literature consistently cites the ratio of males to females as being at least 5:1.<sup>8</sup> Our patient is a female and that is quite rare. It is common in sixth and seventh decades of life usually in individuals with a short and heavy built. Smoking was found to be an important risk factor for the occurrence

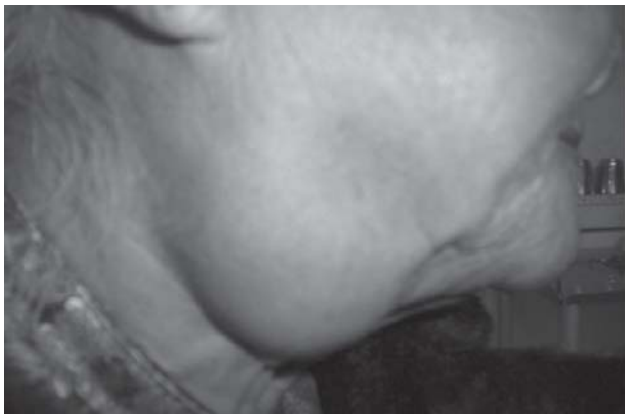## Warthin's tumor of Submandibular gland

of this tumour.<sup>4</sup> Kotwall et al demonstrated an eightfold risk of developing Warthin's tumour in smokers compared to non-smokers.<sup>9</sup> However the exact mechanism is still obscure.

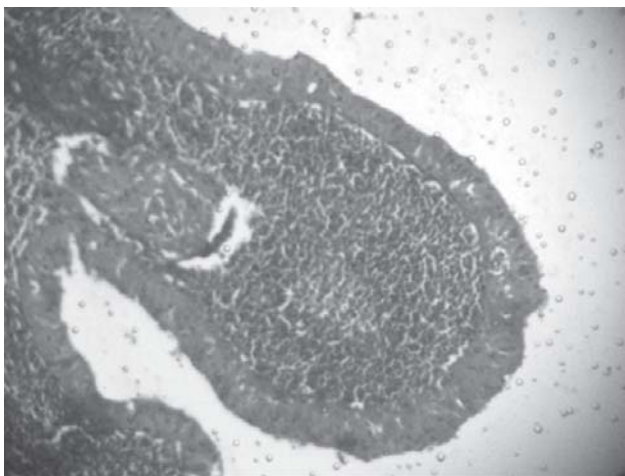
Warthin's tumour is generally asymptomatic. Only 10% of patients are reported to have symptoms such as pain, pressure sensation or facial nerve weakness other than the mass.<sup>3</sup> Treatment of warthin's tumour is complete excision. Recurrences will not occur if there is a total removal. Malignant transformation of warthin's tumour is extremely rare<sup>3</sup> and malignant transformation rates ranging from 0.06 to 0.3% have been reported.<sup>10</sup>

### Conclusion

Although extraparotid Warthin's tumour is extremely rare, it should also be considered as a differential diagnosis in a typical swelling of the submandibular salivary gland prior to definite treatment. Complete excision is the treatment of choice.



**Fig.1.** Warthin's tumour in the right submandibular region



**Fig.2.** Microscopic features of the Warthin's tumor

### References

1. M Ellies, R Laskalvi, C Arglebe. Extraglandular warthin's tumors: clinical evaluation and long term follow up. *British Journal of Oral and Maxillofacial Surgery* 1998; **36**:52-53.
2. Wackym PA, Gray GF Jr, Rosenfeld L, Friedmann I. Papillary cystic oncocytoma and warthin's tumor of the parotid gland. *J Laryngol Otol* 1986; **100**:679-686.
3. Batsakis JG, EI Nagger A. Pathology consultation: warthin's tumor. *Ann Otol Rhinol Laryngol* 1990; **99**:588-91.
4. Keyers JW, Harkness BA, Greven KM, Williams DW 3rd, Watson NE Jr McGuirt WF. Salivary gland tumors: pretherapy evaluation with PET. *Radiology* 1994; **192**:99-102.
5. Albrecht H, Arzt L. Papillare cystadenome in Lymphdrusen. *Frankfurt Z Pathol* 1910; **4**:47-69.
6. Warthin AS. Papillary cystadenoma lymphatosum. *J Cancer Res* 1929; **13**:116-25.
7. Fantozzi DR, Bone RC, Fox R. Extraglandular warthin's tumor. *Laryngoscope* 1985; **95**:682-688.
8. Chapnik JS. The controversy of warthin's tumor. *Laryngoscope* 1983; **93**:695-716.
9. Kotwall C. Smoking as an etiologic factor in the development of warthin's tumor of the parotid gland. *Am J Surg* 1992; **164**:646-7.
10. Patterson JW, Wright ED, Camden S. Extra parotid warthin's tumor. *J AM Acad Dermatol* 1999; **40**:468-470.