

Spontaneous omental hematoma

R. S. Bhandari, R. Sapkota, P. Mishra, K. P. Singh

Department of Surgery, Tribhuvan University Teaching Hospital, Kathmandu, Nepal.

Correspondence to: Dr Ramesh Singh Bhandari, lecturer, Department of Surgery, Tribhuvan University Teaching Hospital, Kathmandu, Nepal

e-mail: rameshbhandari@yahoo.co.in

Abstract: Spontaneous omental bleeding is a rare entity, and usually presents with various combination of sudden abdominal pain, shock, peritonitis and hemoperitoneum. A 68 year female presenting with acute abdomen and without antecedent trauma had obscure hemoperitoneum. Exploration revealed hemoperitoneum and hemorrhagic omentum with a huge clot.

Key Words: Spontaneous omental hematoma, acute abdomen, hemoperitoneum, surgery.

Introduction

Omental hematoma is usually a result of abdominal trauma. Spontaneous omental hematoma (also called idiopathic omental hematoma) is a rare entity, and usually presents with sudden abdominal pain and hemoperitoneum, the so called abdominal apoplexy. Herein, we report a case of spontaneous omental bleeding, presenting as obscure hemoperitoneum.

The case

With no antecedent trauma, a 68 year lady in good health had sudden onset, progressive upper abdominal pain which later became generalized. It was associated with profuse vomiting and gradually increasing abdominal distension. After few hours of pain, she had passed a little amount of loose stool but not flatus. Apart from a pyelolithotomy 10 years back, her past history was not significant. When she presented to the emergency room after 40 hours of symptoms, she was in severe pain; pale, tachycardiac and dehydrated, with a normal blood pressure. Examination revealed a distended abdomen with peritonitis. An initial hematocrit of 21% was in par with severe clinical pallor, and warranted some search for intra-abdominal bleeding. With simultaneous resuscitation with crystalloids and colloids including blood, she was subjected to an abdominal ultrasound (US). Moderate ascitis was the only positive US finding, and frank blood subsequently aspirated confirmed hemoperitoneum. Computed tomography (CT)

of abdomen showed, in addition to ascitis, a heterogeneous, poorly enhancing mass encasing the bowel loops and adherent to the lumbar abdominal wall (Fig. A,B). Coagulation profile was normal. In retrospect, there was no history of intake of drugs including aspirin, and of features suggesting bleeding disorders.

With the diagnosis of hemoperitoneum of obscure origin, laparotomy was done. There were two liters of blood in the peritoneal cavity but no active bleeders were identified. A hemorrhagic greater omentum enmeshed with a huge clot (500 ml) was seen (Fig. C) and the rest of the abdominal organs were normal. Subtotal omentectomy was done and hemostasis was secured. There was no evidence of trauma in any viscera and also in the peritoneal surface of anterior abdominal wall.

The patient recovered well and was discharged home after 5 days of uneventful hospital stay. Histopathological examination of the resected tissue showed omental hematoma without any features of tumor or granulomas. She has remained asymptomatic during 4 months of follow-up.

Discussion

First reported in 1896 by Bush, vascular pathologies of omentum are still uncommon.¹ The major cause of omental hematoma is trauma, including seat belt injury in high velocity accidents.² There have been reports of spontaneous

Spontaneous omental hematoma

omental bleeding possibly linked to rupture or dissection of gastroepiploic vessels^{2,3,4,5,6,7}; polycythemia vera⁸; chronic pancreatitis⁹ and systemic lupus erythematosus¹⁰. Two cases reported had ruptured aneurysm of the omental arteries themselves.^{7,11} Masive omental bleed has been noted in patients with segmental mediolar arteritis¹² and severe necrotizing vasculitis due to rheumatoid arthritis, amyloidosis and Wegener's granulomatosis.^{13,14} Omental bleeding secondary to ruptured primary or secondary omental pregnancy have been reported.^{15,16,17} Chang et al have reported a spontaneous lesser omental bleeding in a G-6PD deficient patient.¹⁸ Omental tumours, rare entities by themselves, may rarely bleed.¹⁹ Occasioanally, omental torsion has been reported to have given rise to spontaneous bleeding.²⁰ A case of omental hematoma reported in the pilot of a fighter jet was explained on the basis of a rapid blood flow shift due to high speed.² Often, no comorbidity is found, as in our case.

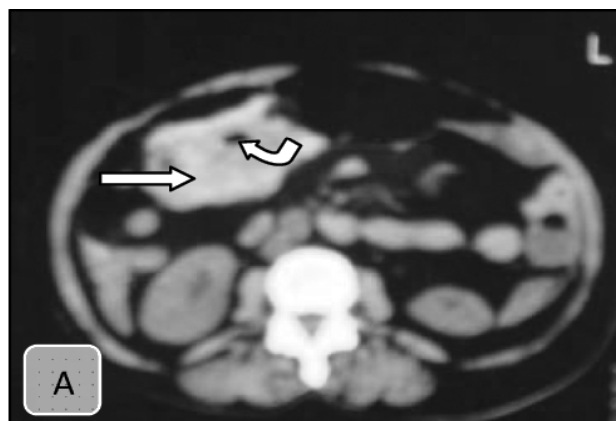
Most of the cases reported with apparent association with other clinical entities are elderly patients, whereas truly spontaneous hematomas are found in young patients. No specific age and sex predilection has been found in the literature. Most common presentation is that of an acute abdomen and not uncommonly, patients may present in shock.^{21,22} Though localized hematomas occur, hemoperitoneum often dominates the picture.

US, US-guided peritoneal tap, CT, magnetic resonance imaging and angiography have been used for diagnosis.^{2,8,9,21,22,23} But usually clinical picture of acute abdomen guides treatment and accurate preoperative diagnosis may not be available and at times not necessary. Imaging studies may help to rule out other abdominal pathologies and in following patients managed conservatively.^{2,23}

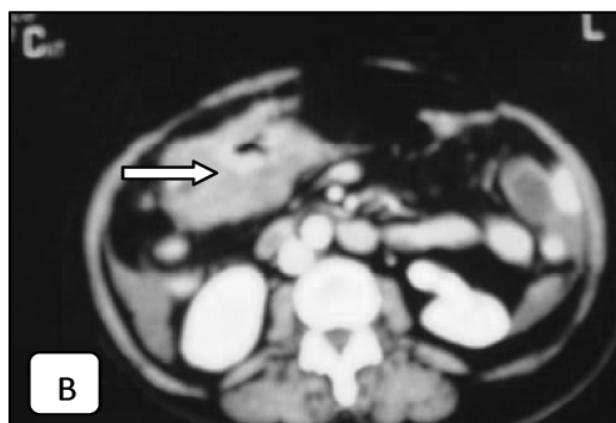
As in any acute abdominal catastrophe, resuscitation gets the priority; and usually surgery is the definite treatment, although vigilant non-operative management has been tried with mixed results.^{21,23} When the latter fails, patients have to be operated. Surgery usually involves excision of the omentum with the hematoma, and is usually curative. Successful use of laparoscopy has been recently reported.²⁴ Recurrence of bleeding after surgery has not been reported to date in available literature.

Conclusion

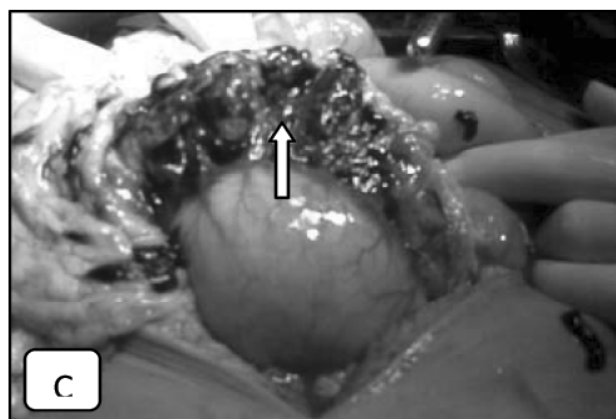
It is important to consider spontaneous omental bleeding as a rare differential diagnosis of acute abdomen. Prompt and proper diagnosis and management produces favorable outcome.



Figures. A, Heterogeneous mass (*horizontal arrows*) near the stomach lumen (*curved arrow*).



B, The mass enhances poorly with contrast.



C, Hemorrhagic omentum enmeshed with clot (*vertical arrow*).

References

1. Montiel A J, Sanabria M, Sanchez J G, Iturbide J, Sandoval M V H, Ramos G. Vascular pathology of the

- greater omentum: report of two cases. *Eur J Gen Med* 2004;**1(3)**: 45-48.
2. Ghiatas AA, Fischer R. CT of spontaneous hematoma of omentum. *Eur Radiol* 1994;**4**:474-5.
 3. Rohtagi A, Cherian T. Spontaneous rupture of a left gastroepiploic artery aneurysm. *J Postgrad Med* 2002;**48**:288-9.
 4. Gibb W R, Archer T J, Van der walt J D. Hemoperitoneum caused by a dissecting aneurysm of the left gastric artery. *Postgrad Med J* 1982; **58(677)**:185-6.
 5. Michas C A, Pollak E W, Wolfman E F Jr. Hemoperitoneum due to spontaneous gastroepiploic artery rupture. *JAMA* 1977;**237(23)**:2526.
 6. Borioni R, Garofalo M, Innocenti P, Fittipaldi D, Tempesta P, Clagrande L. Hemoperitoneum due to spontaneous rupture of an aneurysm of the left gastroepiploic artery. *J Cardiovasc Surg* 1999;**40(1)**: 63-4.
 7. Bettini N, Goueffic Y, Marret O, Heymann M F, Costargent A, Patra P, et al. Hemoperitoneum due to rupture of an omental arterial aneurysm. *J Chir* 2007;**144(6)**:544-5.
 8. Maehara Y, Fujisaki T, Yokota E. Spontaneous omental bleeding presenting as acute abdomen during treatment for polycythemia vera. *Rinsho Ketsueki* 2005;**46(20)**:141-3.
 9. Masatoshi I, Norio A, Aashiko M, Hiroyuki S, Tetsuya S, Makoto S. *J Abd Em Med* 2001;**2(5)**:855-8.
 10. Yamaguchi M, Kumada K, Sugiyama H, Okamoto E, Ozawa K. Hemoperitoneum due to ruptured gastroepiploic artery aneurysm in systemic lupus erythematosus: a case report and literature review. *J Clin Gastroenterol* 1990;**12(3)**:344-6.
 11. Park D J, Oh K H, Kim S J, Joo K W, Han J S, Kim S, et al. True aneurysm rupture of omental artery leading to hemoperitoneum and shock in a CAPD patient. *Nephrol Dial Transplant* 2005;**20(10)**:2992.
 12. Ohwada S, Joshita T, Kawade S, Tanahashi Y, Takeyoshi I, Lino Y, et al. Intra-abdominal bleeding as a result of segmental mediolytic arteritis of an omental artery: case report. *Vasc Endovasc Surg* 1993;**27(5)**:390-394.
 13. Kroot E J A, Mak C L P, Boelhouwer R U, Middelkoop M P C, Dees A. Involvement of the omentum in Wegener's granulomatosis. *Ann Rheum Dis* 2003;**62**:1238-1239.
 14. Jayawardene, Satishkumar A, Sheerin N, Pattison, James M, David J A, et al. Spontaneous abdominal hemorrhage with amyloid-associated amyloidosis and vasculitis in a patient with rheumatoid arthritis. *J Clin Rheumatol* 2001;**7(2)**:86-90
 15. Onan M A, Turp A B, Saltk A, Akyurek N, Taskiran C, Himmetoglu O. Primary omental pregnancy: case report. *Hum Reprod* 2005;**20(3)**:807-809.
 16. Oznur K, Ozer I, Semra O. Primary omental pregnancy on the gastrocolic ligament. *South Med J* 2007;**100(4)**:403-4.
 17. Tanaka Y, Yokoyama M, Onoyama Y, Nozaki M, Nakano H. Abdominal bleeding from omental trophoblastic implants after laparoscopic salpingostomy. *J Gyn Surg* 2002;**18(4)**:167-70.
 18. Chang W, Lee C, Hsu K, Chheng J, Cheng C. Spontaneous lesser omental bleeding: a case report. *Taiwan J Em Surg* 2007;**9(1)**:27-30.
 19. Crusco F, Chiodi M, Mosca S, Fischer M J, Lupattelli L. Benign omental hemangiopericytoma presenting with hemoperitoneum: radiologic findings. *Am J Rad* 2005;**184**:S67-S69.
 20. Nihei Z, Kojima K, Uehara K, Sawai S, Kakihana M, Hirayama R, et al. Omental bleeding with spontaneously derotated torsion-a case report.
 21. Takahashi H, Adachi Y, Kasahara Y, Maruyama J, Maeda S, Kitagishi H, et al. Two cases of spontaneous omental hematoma. *Acta Medica* 1996;**21(3)**:255-61.
 22. Ohno T, Ogata K, Aiba S, Fukuchi M, Osawa H, Mogi A, et al. Idiopathic omental bleeding: report of a case. *Surg Today* 2005;**35(6)**:493-5.
 23. Hiroaki I, Takayuki Y, Nobuyuki H, Takahiro K. *J Mitoyo Gen Hosp* 2006;**27**:86-8.
 24. Ramos C T, Sammartano R. Laparoscopic omentectomy for omental infarction after bicycle handlebar injury. *J Laparoend Adv Surg Tech* 2008;**18(2)**:327-329.