

Study of sella turcica with associated anomalies in the human skulls

A. K. S. Bilodi

Correspondence to: Dr. A. K. S. Bilodi Department of Anatomy Nepalgunj Medical College Chisapani, Nepal

This present study was done on 150 normal dry human skulls obtained from the 1st Year M.B.B.S. students of Sri Devraj Urs Medical college, Tamaka, Kolar, Karnataka. In thirteen out of one hundred and fifty skulls showed interclinoid bar of bone with carotico clinoid foramen. In nine skulls they were seen on both sides (69.23%) while in four skulls they were only on one side (30.76%). One skull showed complete ossified horizontal bar of bone connecting all the three clinoid processes (7.69%) which is of rare variety that made us interested to study these skulls.

Introduction

Three cranial fossae are present, namely Anterior, Middle and posterior cranial fossae.

Anterior cranial fossa contains frontal lobes of cerebral hemisphere, olfactory nerves and anterior ethmoidal nerves. Its floor forms the roof of the orbit.

Middle cranial fossa is a butterfly shaped having median and lateral part. Median part lodges the pituitary gland in the pituitary fossa, optic chiasma and inter cavernous sinus. Lateral part has cavernous sinus, 3rd to 6th cranial nerves, middle meningeal vessels, greater petrosal and lesser petrosal nerves¹

Posterior Cranial Fossa has clives, foramen magnum, inter occipital crest and internal occipital protuberance. Main contents are cerebellar hemisphere, pons and medulla oblongata¹

Pituitary fossa also known as Hypophyseal fossa. Hypophyseal fossa along with tuberculum sellae and dorsum sellae forms the Sella Turcica resembling a Turkish Saddle.² Pituitary gland, the master endocrine gland also known as the 'conductor of endocrine orchestra' sits on

the throne of sella turcica suspended by the stalk of the infundibulum from floor of the third ventricle.

The roof is diaphragm sella, which is circular fold of duramater attached to anterior clinoid process and posterior clinoid process. The lateral ends of tuberculum sellae show small projections called Middle Clinoid Process (MCP). Sometimes this middle clinoid process is connected to anterior clinoid process by a small bony spicule forming a foramen known as Carotico Clinoid Foramen³

Material and methods

One hundred and fifty dry unbroken human skulls obtained from the bone sets of 1st year M.B. B.S students of Sri Devraj Urs Medical College, Kolar, Karnataka constituted the materials for the present study. The skulls were belonging to unknown sexes. Observation were made around sella turcicas for the presence of all three clinoid processes, inter clinoid bar of bone and carotico clinoid foramen on both sides.. Associated variations like prominent occipital condyles with well developed crista galli and hyper osteotic changes were noted in each skulls. Later this study was well compared and correlated with the earlier workers and with available literatures.

Observations

Table 1 Showing the sides of interclinoid bar of bone, complete Carotico Clinoid Foramina and Incomplete Carotico Clinoid Foramina

S.NO	INTER CLNOID BAR OF BONE		COMPLETE CAROTICO CLINOID FORMEN		IN COMPLETE CAROTICO CLINOID FORAMEN		TYPES THEIR PERCENTAGES
	Right	Left	Right	Left	Right	Left	
1	P	P	P	P	TYPE-1-7.69%
2	P	P	P	P	TYPE-2-23.07%
3	P	P	P	P	TYPE-2-23.07%
4	P	P	P	P	TYPE-2-23.07%
5	P	Absent	P	Absent	TYPE-2-7.69%
6	P	P	P	P	TYPE-3-30.76%
7	P	P	P	P	TYPE-3-30.76%
8	P	P	P	P	TYPE-3—30.76%
9	P	P	P	P	TYPE-3—30.76%
10	P	Absent	P	Absent	TYPE-3-7.69%
11	P	P	P	P	TYPE-4-15.38%
12	P	P	P	P	TYPE-4-15.38%
13	Absent	P	Absent	P	TYPE-4-7.69%

Thirteen out of one hundred and fifty unbroken human skulls, showed the inter clinoid bar of bones and carotico clinoid foramina around the sella turcica. In nine skulls they were bilateral and in four skulls they were unilateral. They were then classified into four Types.

Type 1 The skull showed complete ossified horizontal bar of bone connecting all anterior clinoid process, posterior clinoid process and middle clinoid process, forming a complete osseous ring around the sella turcica which was of rare variety 7.69%. Very few literatures have reported about this variation (*Fig.1*).

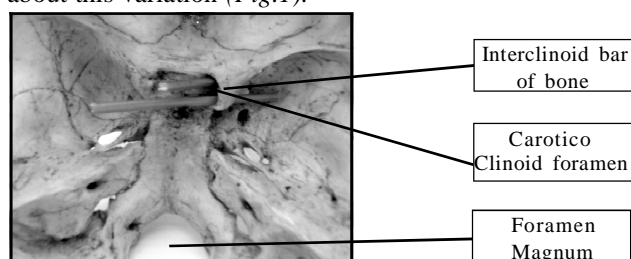


Fig. 1 Showing Sella Turcica with Carotico-clinoid foramen and Interclinoid bar of bone on right side.

Type 2 Variety, three skulls showed inter clinoid bar of bone on both sides connecting anterior clinoid process with middle clinoid process forming a complete carotico clinoid foramen bilaterally through which passes internal carotid artery (23.071%), while in one skull this inter clinoid bar of

bone was seen only on right and absent on the left side (7.69%) where there was no interclinoid bar of bone connecting anterior clinoid process and posterior clinoid process (*Fig. 2*).

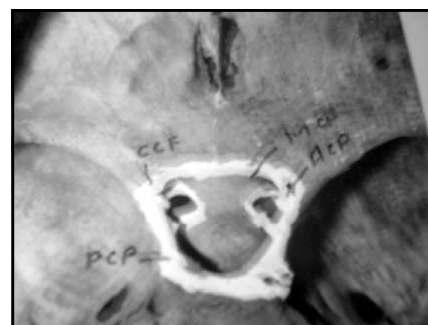

Fig. 2 Showing complete osseous ring of Sella Turcica showing Carotico Clinoid Foramina on both side and complete interclinoid bar of bone on both sides.

As a result three foramina were seen on both sides and two foramina were seen on the left side. Optic foramen transmitting ophthalmic artery and optic nerve. Carotico clinoid foramina transmitting internal carotid artery and middle clinoid foramen, no structures passing.

Type 3 Four skulls showed interclinoid bar of bone connecting anterior clinoid process and posterior clinoid process. From the inferior surface of the horizontal bar a

Study of sella turcica

bony spicule was projecting towards another bony spicule arising from the middle clinoid process, forming an incomplete foramen with a gap of 3mm on both sides (30.76%) known as Incomplete carotico clinoid foramen (Fig. 3).

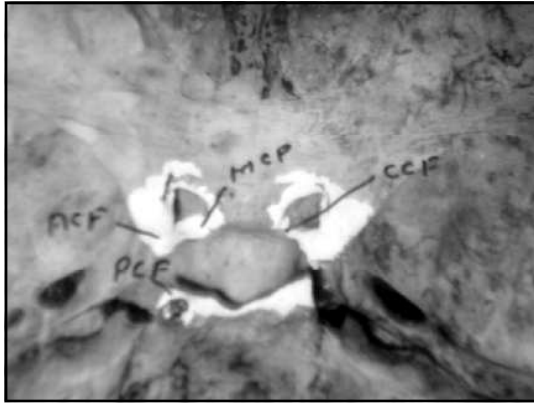


Fig. 3 Photographs showing Carotico Clinoid foramina and Interclinoid bar of bone on both sides.

Another skull showed incomplete carotico clinoid foramen on one side (i.e., on the right side) only (7.69%)

Type 4 Two skulls showed interclinoid bar of bone connecting anterior clinoid process and posterior clinoid process on both the sides (15.38%), and other skull showed on the left side only (7.69%). There was no skull showing horizontal bar of bone connecting anterior clinoid process and middle clinoid process

Rest of the skulls did not show any inter clinoid bar of bones but there were

- A. Prominent occipital condyles in three skulls.
- B. Well developed crista galli in five skulls.
- C. Hyperostotic changes.
- D. Other skulls were normal

Discussion

Normally in living, anterior clinoid process and middle clinoid process are connected by a ligament. This ligament is not seen in the dry human skull but may ossify forming a foramen known as *Caritico clinoid foramen* or *Foramen Clinioideo Carotieum* through which passes the internal carotid artery.

Clinical Importance

Carotico clinoid foramen if present transmits internal carotid artery and also provides protection to the artery while passing through it.

Very few literatures have mentioned about the presence of these foramen. Dubrul (1996)⁴ and Williams (1999)⁵ have

mentioned this foramen but have not mentioned about their prevalence and sides.

Later Patnaik et. al (2003) observed interclinoid bar of bone in the skulls in their study. In one skull, anterior clinoid process and middle clinoid process were inter connected by bony bridge thus creating a foramen known as *Foramen Clinioideo Carotiem* or *Carotico clinoid foramen* on both sides and in another skull the interclinoid bar of bone was connecting anterior clinoid and posterior clinoid processes on both sides. From the middle of this horizontal bar of bone a small bony process was projecting towards another bony process that was arising from the middle clinoid process but they had not fused this forming an incomplete caritco clinoid foramen on both sides This interclinoid bar of bone is said to be due to ossification of duramater extending between above processes.⁶

In the present Study

- 1) Complete ossified horizontal bar of bone connecting the anterior clinoid process, posterior clinoid process, and middle clinoid process was found thus forming a complete osseous ring around the sella turcica in one skull only (7.69%) of type I. This rare type was not observed in the study of Patnaik et al
- 2) The inter clinoid bar of bone, connecting anterior clinoid process with middle clinoid process thus forming, a complete carotico clinioideo foramen or carotico clinoid foramen through which passes internal carotid artery, were observed on both sides in three skulls (23.07%). In one skull this inter clinoid bar of bone was found on right side only. There were no interclinoid bar of bone connecting anterior clinoid process and posterior clinoid process. (7.69%) on the left side
- 3) Similar type horizontal bar of bone connecting anterior clinoid process and posterior clinoid process and incomplete carotico clinoid foramina formed by bony processes arising from both bar of bone as well as from the middle clinoid process were found in four skulls of type 3(30.76%) on both sides and in one skull it was found on one side only (7.69%)

This unilateral presence of incomplete carotico clinoid foramen was not observed in above studies of Patnaik et al.

In two skulls there were interclinoid bar of bones connecting anterior clinoid process with posterior clinoid process on both sides (15.38%) and in one skull it was on one side (7.69%) but there was no inter clinoid bar of bone connecting, anterior clinoid and middle clinoid processes as seen in type 4.

This type of variation was not found in the studies of

Patnaik et al..

On reviewing literatures of Anson (1950)⁷. Thorek (1951)⁸, Hamilton(1950).⁹ Lockharetal(1959)¹⁰ MeMinn (1994)¹¹
The incidence of bilateral inter clinoid bar was not found in their studies, Hence these were studied and reported. These variations of sella turcica may be due to population difference or racial difference

Conclusion

Study on sella turcica helps the neurosurgeons by the presence of interclinoid bar of bone and carotico clinoid foramen through which internal carotid arteries pass. The interclinoid bar of bone protects the above artery while passing through. Interclinoid bar of bone and carotico clinoid foramen have morphological and vascular importance. Hence it has been studied and discussed.

Acknowledgements

My sincere thanks to Anatomy department, Prof and, HOD of Anatomy, students for the material and Principal, Administrative Officer(A.O) of Sri Devraj Urs Medical Collage, Tamaka, Kolar, Karnataka.

References

- 1) Mc Minn. R. M (1997) Last's Anatomy Regional and Applied international Students Edition Ninth Edition Churchill Livingstone 368 71.
- 2) Agur Anne. M.R. (1991) Grant's Atlas of A Anatomy 9th Edition Williams and Wikins 7.35 2 477p.,
- 3) Ranganathan T.S (1993) Text Book of Human Anatomy 5th Edition S Chand and Company New Delhi- 528 29.
- 4) Dubrul E L (1996) Oral Anatomy in the ski. 111 AITBS Publishers and Distributors, **PP** 13.
- 5) Williams. L. H., Berry. M. M., Colin. P. Dyson M, Dussek. J. E , Fergusson M. W' J (1990) Gray's Anatomy in skeletal system, Soames, R. W.: Fdr. 38th Edition Churchill Living Stone, Edinburgh, London: pp547-612
- 6) Patnaik.V.V.K, Singla Rajan K, Bala Sanju (200) Bilateral Foramen Clinoideo Carotieum and inter clinoid Bars A Report of two cases *J Ana. Soc. India* 52; **1**: 69-70.
- 7) Anson, BJ. An atlas of human anatomy: The skull W.B. Saunders CO: Philadelphia: pp 7-8 (1950)
- 8) Thorek .P.: Anatomy in Surgery in skull 2nd Ed. B. Lippincort and Co Philadelphia : London pp 9 28 (1951).
- 9) Hamilton W J. :Text Book of Human Anatomy skull Maj Milton and Co: London pp. 133-34 (1956)..
- 10) Lockhart R.D: Hamilton G.F.F. Anatomy of the human body in: and Joints skull. Fiber and Faber Ltd London: 34 36 and 40. 41(1959).
- 11) Mc. Minn R.M.H.: Last's Anatomy : Regional and applied in Osteology of skull 9th Edition Churchill Living, Stone Edinburgh London pp 643-46(1994).