

How I do it: Bullet removal from head and neck regions.

D. K. Baskota

Associate Professor, Department of ENT-Head & Neck Surgery, Tribhuvan University Teaching Hospital, Post Box No: 3578, Kathmandu, Nepal

Correspondence to: E-mail: dkbaskota@healthnet.org.np.

Abstract:

A retrospective, observational study to find out a reliable, simple and cost effective new technique (*Needle guided technique*) for exact localization and successful removal of bullets from head and neck regions was currently carried out in the Department of ENT- Head & Neck Surgery of Tribhuvan University Teaching Hospital Kathmandu, Nepal. Altogether two bullets of two patients were exactly localized and removed successfully without any complication in this region by applying this new technique.

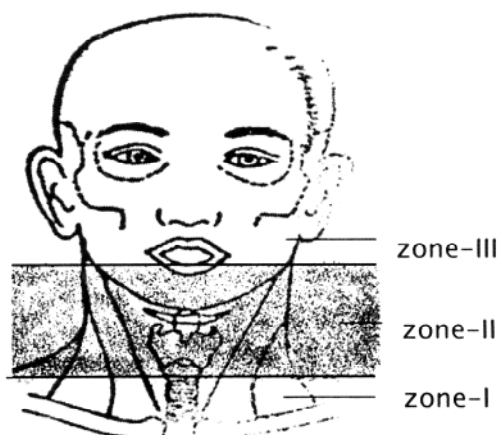
The result of this study so far indicates that “Needle guided technique” is reliable, simple and cost effective technique to localize bullets especially in head and neck regions followed by their successful removal, which is recommended to doctors working without advanced radio diagnostic support and even for those who cannot afford for the advance radio diagnosis.

Introduction:

Bullet injuries are not so uncommon in mechanized modern life as well as life of those parts of the world which are directly affected by present world terrorism. The disease is preponderance to male as males are more exposed. In recent years trauma units of all over the world are faced with an ever-increasing number of gunshot injuries. Neck injury comprises 5-10% of all trauma cases that present.

Gunshot wounds cause tissue injury by three mechanisms: (i) direct tissue injury (ii) temporary cavitations and (iii) transmission of shock waves. From the management point of view, cervico facial regions are divided into three zones to which cervico facial injuries are sited.

Zones of cervico facial region:



- Zone I: area in between the lower border of cricoid cartilage and above the superior mediastinum.
- Zone II: area from the lower border of cricoid cartilage below and up to the line drawn through the angles of mandible above.
- Zone III: area from the line drawn through the angles of mandible below and up to the base of skull above.

As head and neck (cervico facial) regions are very important cosmetically and anatomically (location of great vessels, cranial nerves, spinal cord, sympathetic plexus, thoracic duct, food passage and airway), exact localization of bullets and their removal is mandatory without any delay and extra tissue damages.

But for the exact localization of bullets three-dimensional CT is the choice of investigation, but is very expensive. Due to this reason many victims cannot afford and even in many medical centers this facility is lacking even if the victims can afford it. Considering this fact, a simple, reliable and cost effective method for localization of bullets in the cervico facial region and their successful removal has been highly expected since last one decade and to fulfill this expectation author has tried to explore a new method here.

Since last one decade Nepal is also suffering from terrorism and antisocial activities due to which the number of bullet injuries and blast injuries are dramatically increased in numbers. Here two cases of bullet injuries of cervico facial region are presented individually in which author had exactly localized and removed bullets successfully by applying a new technique designed by the author given the name a “Needle guided technique”

Methodology:

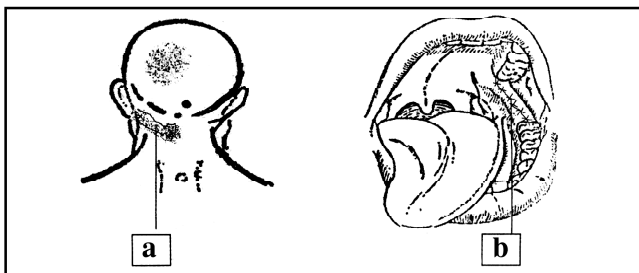
After proper history taking and clinical examination of the patient who had bullet injuries, plane X-rays were assessed and the localization of bullets roughly guessed. Likewise patients were further assessed and investigated for the haemodynamic stability and fitness for general anesthesia after which they were planned for emergency exploration under general anesthesia. In the operation theatre after intubation and proper positioning, parts of the exploration were carefully prepared taking all the precautions of antisepsis and asepsis.

For the localization of bullets by “*Needle-guided technique*” a sterile lumbar puncture needle (Long 26 g needle) was taken and carefully inserted it into the suspected areas where its localization was guessed. The tip of the needle was inserted in different direction till its tip felt a metallic resistance and sound. Care should be taken for the piercing of the great vessels and constantly watched of the outcome from the needle. In the high-risk areas even we can use smaller size of needle to prevent the risk.

After feeling a metallic resistance and sound the needle was kept in situ and most appropriate approach was decided considering its depth and surrounding structures. Soft tissues were dissected keeping the needle as central guide till the bullet was seen; which was localized and removed by artery forceps. All dead tissues or haematoma were removed if present, any damaged structures were repaired and wound was closed in layers with or without its drainage as per cases. Aseptic dressing was done in the operated site and operation was terminated.

Case Report:**Case No 1:**

Mr. MPS 45 year's old male, teacher by profession from Bara district of central developmental region of Nepal attended emergency department of TU Teaching Hospital, Maharajgunj Kathmandu on 17/10/2060 after having a bullet injury in his neck ten hours before his arrival. On examination, patient was haemodynamically stable and fully conscious. ENT-Head and Neck examination revealed a small-lacerated penetrating injury on left side of the nape of his neck and small peticeal hemorrhagic spots in the left peritonsillar region. Likewise he had some fullness in his left side of upper neck. Plane X-ray of soft tissues neck lateral view showed an elongated radio opaque object resembling a bullet near the ramus of left mandible.

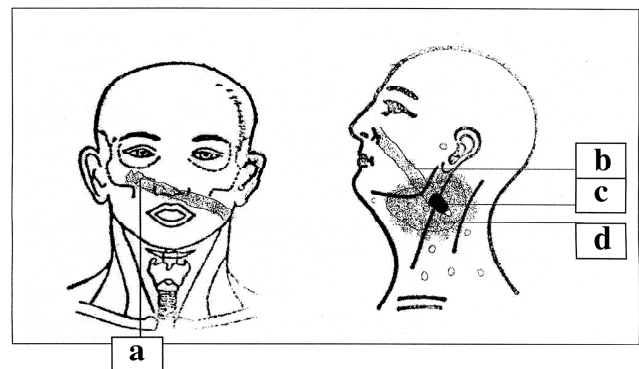
Schematic diagram of case no.1

- entry point of the bullet and its tract*
- retro molar trigone incision from where bullet was removed.*

Patient was prepared for emergency operation during which the bullet was exactly localized by “*Needle guided technique*” in between the fractured medial plate and ascending ramus of left mandible and removed successfully through per oral trans-retromandibular approach. Wound was closed in two layers by approaching the fractured medial plate of mandible in its original position. No intra and postoperative complications were noticed and patient was discharged with absolutely satisfactory condition from the ward on 7th postoperative day.

Case No 2:

Mr. RKS 50 years old male, a policeman from Sunsari district of eastern developmental region of Nepal attended emergency department of TU Teaching Hospital, Maharajgunj Kathmandu on 26/05/2061 after having a bullet injury in his face twenty three hours before his arrival. On examination patient was haemodynamically stable and fully conscious. ENT-Head and Neck examination revealed that there was a small-lacerated penetrating injury on right infra orbital region of his face and diffuse swelling of his left lateral side of the neck. Plane X-ray of soft tissues neck lateral view showed an elongated radio opaque object resembling a bullet near the ramus of left mandible at para pharyngeal space. Likewise plane X-ray of nose and para nasal sinuses showed fracture of Rt. Maxilla without displacement of the fragment and bilateral opaque maxillary antrum.

Schematic diagram case no 2:

- Entry point of the bullet and its tract.*
- Bullet tract in lateral view.*
- Bullet in lateral view.*
- Haematoma formation around bullet.*

Patient was prepared for emergency operation during which the bullet was exactly localized by “*Needle guided technique*” in left para pharyngeal space just medial to carotid sheath and removed successfully through lateral cervical approach. Wound was closed in two layers after evacuating haematoma of the adjacent para pharyngeal space and keeping suction drain at the haematoma site. No intra and

postoperative complications were noticed. Drain was removed on third postoperative day and stitches were removed on sixth postoperative day. Patient was discharged with absolutely satisfactory condition from the ward on 7th postoperative day.

Discussion:

As mentioned earlier, gunshot, blast and penetrating injuries become more common in our country since last few years due to various reasons. As the number of patients is increasing year by year, the medical professionals constantly dealing with these problems should also be trained accordingly. Therefore the curricula of the undergraduate and postgraduate medical programs should be constantly updated accordingly to the need of the new entities that are penetrating into the health care system of the country, targeting to tackle them easily.

Regarding the management of injuries in head and neck regions different experts of different leading medical schools of the world have different opinions and developed their treatment protocols accordingly. But in particular for the removal of bullets from head and neck regions their exact localization is mandatory prior to exploration, with the help of modern radio diagnostic tools.

According to Maisel et al, all penetrating injuries are potentially dangerous and require emergency treatment⁵. But Van et al highlighted slight different opinion for their management and stressed that while the traditional view is that exploration is mandatory for all gunshot wounds to the neck, this issue is now often debated amongst trauma surgeons and focused on careful clinical assessment enhanced with the appropriate investigations which is the cornerstone for deciding to explore a gun shot wound to the neck⁶.

Similarly, Reiss et al in their experience mentioned that principally, one distinguishes ricocheting shots from grazing ones, and those leaving bullets lodged in the body from those with perforating wounds. The extent of tissue damage depends on internal lacerations, of the compressions of the tissue and on the temporary cavitations along the projectile path. In contrast to other types of injuries, which are caused by blow or impact to the face or skull, gunshot traumas are characterized by an irregular path, as well as, by localized destruction of bones with associated effects. In this connection the severity of the bullets wound also depends upon the extent of involvement of the viscerocranium⁷.

Likewise Yetisar et al in their works stressed that patient who sustains gunshot injuries to the head and neck-face; they usually have heavy tissue damage and eventually lead to life threatening conditions. The missile entrance or exit wound may be out of sight in some injuries, and often it is difficult to predict the severity of the injury in the chaotic circumstances of the battlefield⁸.

Shotton in his large series of penetrating neck trauma suggests that covert vascular and aero-digestive tract injuries occur high in the neck⁹. With any penetrating neck wound the first line of management is to establish an airway and resuscitate the patient, then the severity of the injury is assessed and

the detection of covert injuries. If there is any potential vascular compromise, arteriography is indicated provided the patient is reasonably stable. There are different views over the best form of management of penetrating neck wounds. Criteria have been set down for consideration of surgical exploration¹⁰.

In patients who are unstable, there is no doubt that they may need exploration as a life saving procedure. In a series of 314 patients published by Cabasares less than 50% of penetrating neck injuries required immediate neck exploration¹¹. As both of reported patients were stable haemodynamically, both were explored in an emergency basis and bullets were removed successfully with primary repair of the wound after localization of bullets by “*Needle guided method*”.

Conclusion:

Needle guided technique is a simple, reliable and cost effective technique for the exact localization and successful removal of bullets from the head and neck regions which is recommended to doctors working without advanced radio-diagnostic support and even for those who cannot afford for the advance radio-diagnosis.

Acknowledgement:

I am grateful to the Director of Tribhuvan University Teaching Hospital Prof. Mahesh Prasad Khakurel who has kindly consented to publish this article from the hospital side. I would like to express my sincere thanks to all faculty members of the Department of ENT-Head and Neck Surgery of TU Teaching Hospital for their creative suggestions. Likewise my hearty thanks go to all our post-graduate residents, especially Dr. Manav Bhattarai and Dr. Sarita KC of the department for helping me during the surgical procedures and subsequent care of the patients during their hospital stay.

References:

1. Uday S. Kale, Savita U. Kale: Penetrating neck trauma caused by an unusual weapon. *Pakistan Journal of Otorhinolaryngology-Head & Neck Surgery*. 2004; **20**:59-60
2. Robert H. Maisel, David B. Hon: Penetrating trauma of the neck. In: Charles W Cummings eds. *Otolaryngology and Head and Neck Surgery*. 3rd ed. **Vol. 3**. St, Luis; Mosby; 1998: 1707
3. Michael G. Stewart: Penetrating face and neck trauma. In: Byron J. Bailey eds. *Head and Neck Surgery- Otolaryngology*. 2nd ed. **Vol. 3**. Philadelphia; Lippincott- Raven; 1998: 1033.
4. Pringle MB, Charig MJ: The use of digital subtraction angiography in penetrating neck injury- a very instructive case. *The Journal of Laryngology and Otology*, 1994; **108**:522-4
5. Robert H. Maisel, David B. Hon: Penetrating trauma of the neck. In: Charles W Cummings eds. *Otolaryngology and head Neck Surgery*.
6. Van As AB, Van Deurzen DF, Verleisdonk EF: Gunshots to the neck: selective angiography as part of conservative management. *Injury*. 2002 June; **33**(5): 453-6
7. Reiss M, Reiss G, Pilling E: Gunshot injuries in the head-neck area-basic principles, diagnosis and management. *Schweiz Rundsch med Prax*. 1998 June 10; **87**(24):832-8.

8. Yetser S, Kaharamanyal M: High velocity gunshot wounds to the head and neck: a review of wound ballistics. *Mil Med.* 1998 May; **163**(5): 346-51
9. Shotton JC: stab wounds of the neck-observation on management. *Clinical Otolaryngology.* 1988; **13**:335-9.
10. Pringle MB, Chairg MJ: The use of digital subtraction angiography in penetrating neck injury-a very instructive case. *The Journal of Laryngology and Otology*, 1994; **108**:522-4
11. Cabassres HV: Selective surgical management of penetrating neck trauma. *The American surgeon.* 1982; **48**:355-8