

Thickness of Neurocranium Bones of Deceased Adults: A Cross-Sectional Study

Kumar Bhushal¹, Bidur Adhikari², Rosha Bhandari², Deepesh Dhungel², Jyoti Gautam², Subina Gautam², Navindra Phuyal³, Anusuya Shrestha²

Author(s) affiliation

¹Department of Anatomy, Madan Bhandari Academy of Health Sciences, Hetauda, Nepal

¹Department of Anatomy, Maharajgunj Medical Campus, Institute of Medicine, Tribhuvan University Teaching Hospital, Kathmandu, Nepal

³Department of Anatomy, Rapti Academy of Health Sciences, Dang, Nepal

Corresponding author

Anusuya Shrestha, MBBS, MS
shrdwa1anshu@gmail.com

DOI

[10.59779/jiomnepal.1447](https://doi.org/10.59779/jiomnepal.1447)

Submitted

Oct 11, 2025

Accepted

Dec 15, 2025

ABSTRACT

Introduction

Thickness of neurocranium is not regular throughout the skull and cranial vault thickness is often observed to be higher in females when compared to males. This study aimed to measure the thickness of neurocranium of deceased adults and compare it across sex, age and laterality.

Methods

This was a cross-sectional study in which 72 deceased adults were enrolled, that presented in the mortuary of the Department of Forensic Medicine and Department of Anatomy of Maharajgunj Medical Campus. Measurements were taken after ethical approval from Institutional Review Committee of Institute of Medicine and after obtaining written informed consent from the relatives of the deceased. Measurements were taken in 9 points total, using an iGaging 8" Digital Outside Caliper. Independent sample t-test was done to compare the thickness between sexes and one-way ANOVA was done to compare the thickness between the bones.

Results

The mean thickness of frontal, parietal, temporal, occipital bones, and pterion were 5.38(±0.91), 4.67(±0.59), 1.52(±0.50), 6.53(±1.28) and 2.55(±0.74) mm respectively. Thickest point was Occipital Point B with mean thickness of 7.39(±1.70) mm in females and 8.47(±1.46) mm in males and the thinnest point was found to be the squamous part of temporal bone with the mean thickness of 1.48(±0.69) mm in the right 1.65(±0.69) mm in the left cranium of females and 1.43(±0.41) mm in the right and 1.56(±0.40) mm in the left cranium of the males.

Conclusion

Occipital bone was the thickest bone in the neurocranium and the thickness increased from anterior to posterior side. This study will be helpful for surgeons in bone grafting and selecting screws and will also be resourceful to anatomists and anthropologists.

Keywords

Bone; deceased; neurocranium; thickness

INTRODUCTION

The neurocranium of the skull is subdivided into the calvaria and the basicranium. Calvaria forming bones are flat and formed by intramembranous ossification derived from neural crest cells.¹ The two tables, outer and inner, can be split for autograft and is often used during maxillofacial reconstruction.²

Severity of the brain injuries induced by trauma is affected by the thickness of the skull bones where higher peak accelerations are required for thicker skulls to reach the peak shear stress level.³ Cranial vault thickness has been observed to be higher in females when compared to males and age-related thinning of the frontal cranial vault have also been observed.⁴ Idiopathic Intracranial Hypertension (IIH) has been associated with thinning of the calvaria and the skull base without zygoma(extracranial) thinning.^{5,6} Similarly, intracranial thinning has also been observed in patients with obstructive sleep apnoea that may be associated with spontaneous cerebrospinal fluid leaks.⁷ Topographical mapping of the calvaria is supposed to assist surgeons while specifying the area for cranial bone graft harvest.⁸

The thickness of the skull bones varies in different points.^{2,9,10} Established textbooks of anatomy and forensic medicine clearly lack in mentioning the thickness of skull in autopsy cases.^{1,2} Few studies done in Nepal are based on the dried skull bone and a gap in database regarding the thickness of Nepalese skull persists.^{3,10} The aim of this study was to measure the thickness of neurocranium of adult deceased Nepalese and to compare it in respect to sex, in between the bones and laterality, and report a baseline data.

METHODS

The research method employed was descriptive, cross-sectional. This study involved 72 deceased adults that presented in the mortuary of the Department of Forensic Medicine and Department of Anatomy of Maharajgunj Medical Campus, Kathmandu from May 9th, 2023 to April 2nd, 2024.

Sample size was calculated using the formula $(n) = ((Z \sigma)/E)^2$

Where,

- Confidence level corresponding to the level of confidence of 95% (Z) = 1.96
- Expected SD as per previous study (σ) = 1.67¹¹
- Absolute error (precision) (d) = 0.05
- Mean as per previous study = 8.2¹¹
- Margin of error (E) = Mean \times Absolute error = $8.2 \times 0.05 = 0.41$

Thus, the sample size was, $(1.96 \times 1.67)/0.41 = 64$.

Measurements were taken from 72 deceased adults after ethical approval was obtained from the Institutional Review Committee (IRC) of Institute of Medicine (IOM) and written informed consent was taken from the relatives of the deceased. All the deceased Nepalese adults above 18 years were included in the study and cadavers with head injuries or with gross visible pathologies and deformities of the bones were excluded.

Skull scalp incision, calvaria opening, and extraction of brain lobes were done following standard autopsy procedure.¹² After the removal of the brain, the folds of the dura mater were removed using artery forceps and scalpel. The muscle and the fascia remaining in the temporal fossa were also cleaned. The thickness of nine clinically important

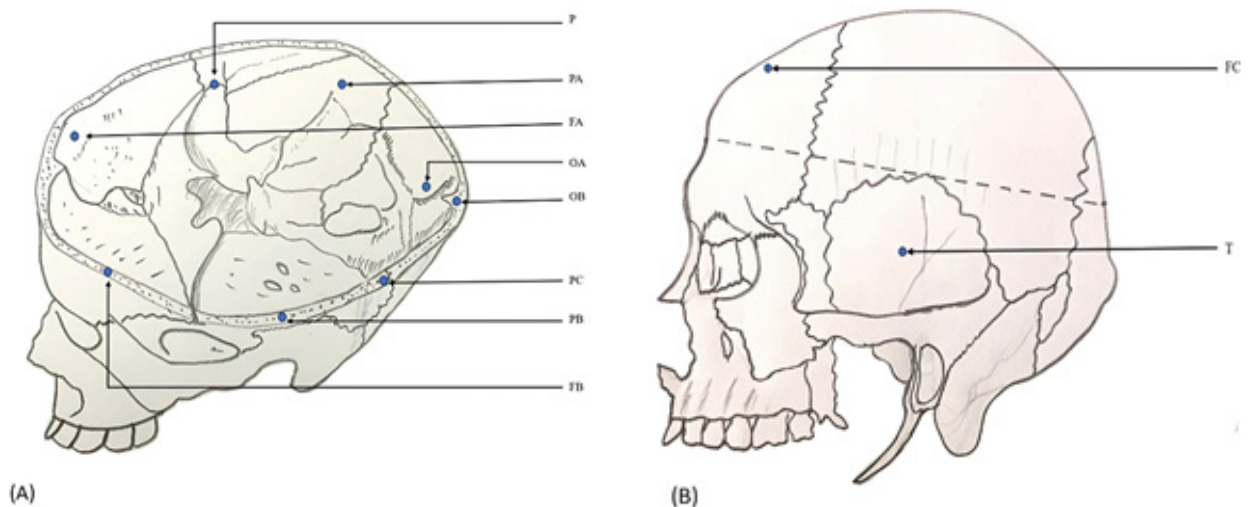


Figure 1. Investigator's illustration of the skull of the measured points. Cutting level: 2 cm above the supraorbital margin anteriorly and 2 cm above the inion posteriorly. (A) Frontal bone A (FA): Frontal bone B (FB): Pterion (P): Parietal bone A (PA): Parietal bone B (PB): Parietal bone C (PC): Occipital bone A (OA): Occipital bone B (OB). (B) Frontal bone C (FC), Temporal bone (T).

points was measured, using an iGaging 8" Digital Outside Caliper bilaterally and one unilaterally in the midline.

Frontal bone was measured bilaterally in three points; Frontal bone A (located 1 cm above the supraorbital margin and 1.5 cm lateral to the midline). Frontal bone B (located at the midpoint of the frontal midpoint and the frontoparietal suture on the cut edge). Frontal bone C (located at the midpoint of the vertex and frontal bone B). The thickness of the pterion on both sides was taken (located 4 cm above the zygomatic arch and 3.5 cm behind the fronto-zygomatic suture). The thickness of the temporal bone on both sides was taken in the midpoint of its squamous portion.

The thickness of parietal bone of each side was taken in 3 points; Parietal bone A (located 1.5 cm below the middle meningeal groove). Parietal bones B and C (divided at the distances between the frontoparietal suture and the occipital midpoint with a ratio of 1:3 and 2:3 respectively in the cut edge). The thickness of the occipital bone was taken bilaterally in two points; Occipital bone A (located 1.5 cm lateral to the midline and 0.5 cm above the inion) and Occipital bone B (located occipital to the midpoint and 2 cm above the inion). Measurements were taken in above mentioned points and as

illustrated in Figure 1

Measurements were taken by the single investigator twice and an average was noted in proforma later entered in Excel sheet. Samples with incomplete and highly skewed data were omitted. Statistical analysis was done using SPSS version 18. Descriptive statistics of various parameters with mean, median, and standard deviation were calculated. The level of confidence was set at 95%, with a level of significance of 0.05. Independent sample t-test and One-Way ANOVA, were used to compare thickness of right and left sides across sexes and to compare the mean of the thickness in between the bones respectively. R programming language (RStudio 2026.01.0, Build 392) was used for data visualization.

RESULTS

In this study, a total of 72 corpses were included among which 46 were male and 26 were female, showing male predominance. They belonged to the age ranging from 18 to 90 years with a mean age of 43.40(±18.85).

The Independent sample t-test was applied to compare the thickness of different points of neurocranium bones across sexes. Table 2. Shows

Table 1. Measurements of neurocranium bones

| Parameters | Total (n) | Minimum (mm) | Maximum (mm) | Mean (mm) | Std. Deviation |
|------------|-----------|--------------|--------------|-----------|----------------|
| RFA | 72 | 2.1 | 8.1 | 4.76 | 1.15 |
| RFB | 72 | 3.1 | 8.5 | 4.94 | 0.96 |
| RFC | 72 | 3.4 | 8.6 | 6.04 | 1.23 |
| LFA | 72 | 2.8 | 8.3 | 5.05 | 1.16 |
| LFB | 72 | 2.5 | 7.9 | 5.17 | 0.94 |
| LFC | 72 | 2.9 | 9.5 | 6.30 | 1.35 |
| RPA | 72 | 1.9 | 7.4 | 4.23 | 0.94 |
| RPB | 72 | 2.0 | 6.3 | 4.10 | 0.86 |
| RPC | 72 | 2.2 | 9.0 | 5.54 | 1.26 |
| LPA | 72 | 2.0 | 7.3 | 4.32 | 0.87 |
| LPB | 72 | 2.7 | 7.0 | 4.43 | 0.87 |
| LPC | 72 | 2.3 | 7.4 | 5.41 | 1.02 |
| RP | 72 | 1.0 | 4.5 | 2.45 | 0.80 |
| LP | 72 | 1.1 | 4.4 | 2.66 | 0.78 |
| RT | 72 | 0.4 | 3.6 | 1.45 | 0.53 |
| LT | 72 | 0.5 | 3.5 | 1.59 | 0.52 |
| ROA | 72 | 2.8 | 9.3 | 5.66 | 1.25 |
| LOA | 72 | 2.3 | 9.6 | 5.85 | 1.32 |
| OB | 72 | 4.9 | 12.0 | 8.08 | 1.62 |

Table 2. Comparison of frontal bone, parietal bone, pterion, temporal bone and occipital bone of right and left side in male and female population

| Parameters | Male | | Female | | Sig. (2-tailed) |
|------------|-------------|------|-------------|------|-----------------|
| | Mean(mm) | SE | Mean(mm) | SE | |
| RFA | 4.60(±1.00) | 0.14 | 5.05(±1.33) | 0.26 | 0.136 |
| RFB | 4.84(±1.04) | 0.15 | 5.13(±0.77) | 0.15 | 0.180 |
| RFC | 6.08(±1.27) | 0.18 | 5.95(±1.17) | 0.23 | 0.660 |
| LFA | 4.82(±1.10) | 0.15 | 5.46(±1.30) | 0.25 | 0.035 |
| LFB | 5.07(±1.01) | 0.14 | 5.35(±0.77) | 0.15 | 0.202 |
| LFC | 6.31(±1.44) | 0.21 | 6.27(±1.20) | 0.23 | 0.910 |
| RPA | 4.14(±0.87) | 0.12 | 4.39(±1.06) | 0.20 | 0.315 |
| RPB | 4.03(±0.94) | 0.13 | 4.23(±0.69) | 0.13 | 0.330 |
| RPC | 5.51(±1.33) | 0.19 | 5.60(±1.14) | 0.22 | 0.777 |
| LPA | 4.35(±0.94) | 0.13 | 4.26(±0.75) | 0.14 | 0.650 |
| LPB | 4.29(±0.93) | 0.13 | 4.67(±0.70) | 0.13 | 0.052 |
| LPC | 5.45(±1.10) | 0.16 | 5.34(±0.88) | 0.17 | 0.647 |
| RP | 2.51(±0.82) | 0.12 | 2.35(±0.76) | 0.15 | 0.395 |
| LP | 2.65(±0.72) | 0.10 | 2.67(±0.88) | 0.17 | 0.919 |
| RT | 1.43(±0.41) | 0.06 | 1.48(±0.69) | 0.13 | 0.750 |
| LT | 1.56(±0.40) | 0.05 | 1.65(±0.69) | 0.13 | 0.562 |
| ROA | 5.83(±1.21) | 0.17 | 5.38(±1.27) | 0.25 | 0.149 |
| LOA | 5.94(±1.30) | 0.19 | 5.68(±1.37) | 0.27 | 0.429 |
| OB | 8.47(±1.46) | 0.21 | 7.39(±1.70) | 0.33 | 0.010 |

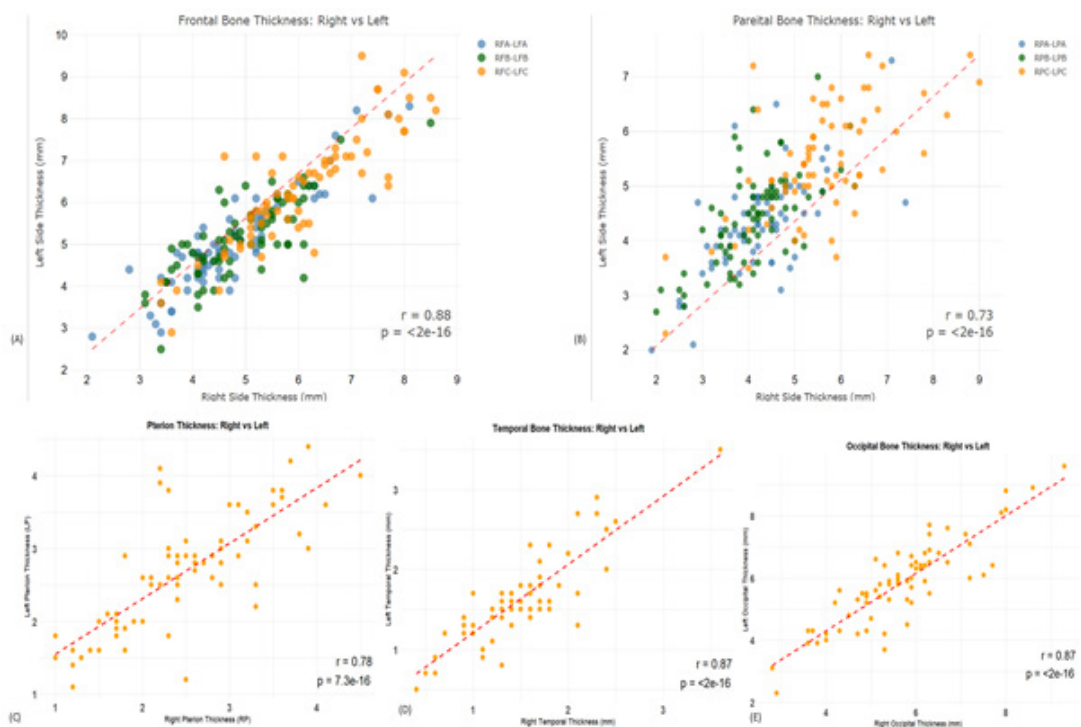


Figure 2. Scatter plot showing thickness of bones and their correlation. (A) Between right and left frontal bones (B) Between right and left parietal bones (C) Between right and left pterion (D) Between right and left temporal bones (E) Between right and left occipital bones.

Table 3. Comparison of mean thickness of bones and bony points with each other

| Bones and bony points | Bones and bony points | Mean Difference | Std. Error | Sig. | 95% Confidence Interval | |
|-----------------------|-----------------------|-----------------|------------|--------|-------------------------|-------------|
| | | | | | Lower Bound | Upper Bound |
| Frontal | Temporal | 3.86 | 0.14 | <0.001 | 3.47 | 4.25 |
| | Parietal | 0.71 | 0.14 | <0.001 | 0.32 | 1.10 |
| | Occipital | -1.15 | 0.14 | <0.001 | -1.54 | -0.76 |
| | Pterion | 2.82 | 0.14 | <0.001 | 2.43 | 3.21 |
| Temporal | Frontal | -3.86 | 0.14 | <0.001 | -4.25 | -3.47 |
| | Parietal | -3.15 | 0.14 | <0.001 | -3.54 | -2.76 |
| | Occipital | -5.01 | 0.14 | <0.001 | -5.40 | -4.62 |
| | Pterion | -1.04 | 0.14 | <0.001 | -1.43 | -0.65 |
| Parietal | Frontal | -0.71 | 0.14 | <0.001 | -1.10 | -0.32 |
| | Temporal | 3.15 | 0.14 | <0.001 | 2.76 | 3.54 |
| | Occipital | -1.86 | 0.14 | <0.001 | -2.25 | -1.47 |
| | Pterion | 2.12 | 0.14 | <0.001 | 1.73 | 2.51 |
| Occipital | Frontal | 1.15 | 0.14 | <0.001 | 0.76 | 1.54 |
| | Temporal | 5.01 | 0.14 | <0.001 | 4.62 | 5.40 |
| | Parietal | 1.86 | 0.14 | <0.001 | 1.47 | 2.25 |
| | Pterion | 3.98 | 0.14 | <0.001 | 3.59 | 4.37 |
| Pterion | Frontal | -2.82 | 0.14 | <0.001 | -3.21 | -2.43 |
| | Temporal | 1.04 | 0.14 | <0.001 | 0.65 | 1.43 |
| | Parietal | -2.12 | 0.14 | <0.001 | -2.51 | -1.73 |
| | Occipital | -3.98 | 0.14 | <0.001 | -4.37 | -3.59 |

comparison of frontal, parietal temporal and occipital bones, and pterion, of right and left side in males and females.

The mean thickness of frontal, parietal, temporal, occipital bones, and pterion were 5.38 (±0.91), 4.67 (±0.59), 1.52 (±0.50), 6.53 (±1.28) and 2.55 (±0.74) mm respectively. With the use of one way-ANOVA and Tukey HSD, comparison of the mean of the bones was done as shown in Table 3.

As shown in Figure 2, all five cranial bones exhibited significant positive correlations between the right and left sides, indicating overall bilateral symmetry. The frontal bone (Figure 2A) demonstrated a significantly strong correlation ($r = 0.88, p < 2 \times 10^{-16}$), reflecting high symmetry between sides. The parietal bone (Figure 2B) showed a significant but moderate strong correlation ($r = 0.73, p < 2 \times 10^{-16}$), suggesting slightly greater variability between sides compared to other bones. The Pterion (Figure 2C) exhibited a strong correlation ($r = 0.78, p = 7.3 \times 10^{-16}$), while the temporal (Figure 2D) and occipital bones (Figure 2E) both showed strong correlations ($r = 0.87, p < 2 \times 10^{-16}$), indicating significant bilateral symmetry.

DISCUSSION

In this study, the mean thickness of frontal, parietal, temporal, occipital bones and pterion was observed as 5.38(±0.91), 4.67(±0.59), 1.52(±0.50), 6.53(±1.28), and 2.55(±0.74) mm, respectively. The result showed significant differences in the thickness of all the measured bones. Similarly, it was also observed that there was significant variation in thickness at various points and occipital bone was the thickest. It was comparable to the findings of previous studies.^{8,10,13} The study done by Baral et al. showed that mean thickness of frontal bone was (5.6±0.8) mm, the parietal bone was (4.5±0.6) mm, and the occipital bone was (8.5±0.7) mm in the Nepalese dry skull.¹⁰ The thickness of frontal and parietal bones were almost similar in this study whereas occipital bone was reported to be thicker. Furthermore, thickness of pterion and temporal bones were added in present study. The radiological mapping of Nepalese calvaria found the mean thicknesses of the frontal, parietal, and occipital bone as (6.1±1.8), (4.6±2.2), and (9.5±3.4) mm, respectively.¹⁴ The thickness of occipital bones was higher compared to present study

and the study done by Baral et al. The difference may be attributed to the physical measurements of the neurocranium rather than the radiological data. Whereas in another study done by Thulung et al. overall thickness of all the bones was seen to be higher with values (8.02±1.97), (7.04±1.43), (4.71±1.34), (7.98±2.47) mm for frontal, parietal, temporal, and occipital bones, respectively.³ The mean thickness of the skull across all locations was 6.32±0.7 mm in a study done by Moreira-Gonzalez et al.⁸

In this study, measurements were taken on three points of frontal, parietal, occipital and one point of temporal bones. As seen in table 1, the thickest point was near the external occipital protuberance on the occipital bone, while the thinnest point was at the midpoint of the squamous part of the temporal bone. This demonstrates a distinct regional variation in neurocranium thickness. The thickness of the frontal and parietal bones increased anterior to posterior illustrating the anteroposterior gradient. The thickness of the pterion was less than the frontal, parietal, and occipital and greater than the squamous part of the temporal bone. The posterior points were found to be thicker compared to the anterior ones in other studies as well. These findings advocate a greater structural reinforcement in the posterior neurocranium providing enhanced protection to underlying structures. It also suggests that greater drilling force is required in posterior cranial screw placement.

The LFA and OB were statistically significant with $P = 0.035$ and $P = 0.010$ respectively, whilst the remaining points were not. In comparison, differences between male and female skulls were greater toward the rear of the parietal bones.⁸ Thickness of bones of females were found to be greater while compared to males^{8,15-17} Contrary to this Pensler et.al. measured the thickness frontal and parietal on the calvaria and they mentioned that the parietal thickness of men exceeded that of women.¹⁸ Another study done in Danish people found that males and females did not differ significantly in cranial thickness, except for right euryon where there was a statistically significant difference with females having the thickest measures.¹⁹ In a study done between whites and blacks it was found that the frontal bone was thicker in white males while parieto-occipital bones were thicker in blacks, than in whites, and in certain age groups, the females in both races had significantly thicker parietal and occipital bones than their male counterparts.¹⁵

This study may be helpful in reconstructive plastic surgeries as the skull is a frequently used site of bone graft harvest. The data on neurocranium thickness may be useful for anatomists, anthropologists, researchers, surgeons, and manufacturers companies of surgical screws. Normal neurocranium

thickness is also a valuable asset to compare with the pathological ones. Body weight, height, ethnicity and race that could have affected the thickness of the skull were not considered in this study. The sample size was also small so that a larger sample size could be taken in future so that the findings can be more generalizable. Pediatric population were excluded in this case which would otherwise provide information about the growth pattern of the neurocranium.

CONCLUSION

The neurocranium is not uniform throughout. Occipital bone was the thickest bone in the neurocranium and the thickness increased from anterior to posterior.

ACKNOWLEDGEMENT

We are greatly indebted to Professor Nirju Ranjit sir for timely guidance and supervision in the research project. We also extend our gratitude towards department of Forensic Medicine for providing study venue.

FINANCIAL SUPPORT

The author(s) did not receive any financial support for the research and/or publication of this article.

CONFLICT OF INTEREST

The author(s) declare that they do not have any conflicts of interest with respect to the research, authorship, and/or publication of this article.

AUTHOR CONTRIBUTIONS

Kumar Bhushal, Principal author: major contribution in research concept, designing, literature review, proposal writing, obtaining research approval from IRC, data collection, data entry and analysis, manuscript preparation.

Bidur Adhikari, co- author: helped in research designing, literature search, and statistical analysis of the study.

Rosha Bhandari, co-author: helped in research proposal preparation and research presentation preparation. Supervision during data collection, data analysis and manuscript editing.

Jyoti Gautam, co-author: helped in literature review and manuscript preparation and editing.

Deepesh Dhungel, co- author: contributed in research conception, conceptual framework preparation, research designing and statistical analysis of data.

Subina Gautam, co-author: helped in research designing and data analysis.

Navindra Phuyal, co-author: contributed in literature search, data analysis and manuscript preparation.

Anusuya Shrestha, corresponding author: contribution in research conception, literature review, data analysis and manuscript editing. Corresponding author is also responsible for correspondence with the editor of the journal.

REFERENCES

1. Dalley AF, Agur AMR, Moore KL. Moore's clinically oriented anatomy. 9th ed. Philadelphia: Wolters Kluwer; 2024.
2. Gray H, Standring S, Anhand N, editors. Gray's anatomy: the anatomical basis of clinical practice. 42nd ed. Amsterdam: Elsevier; 2021.
3. Thulung S, Ranabhat K, Bishokarma S, Gongal DN. Morphometric measurement of cranial vault thickness: a tertiary hospital based study. *JNMA J Nepal Med Assoc.* 2019;57(215):29–32.
4. Goto S, Kataoka K, Isa M, Nakamori K, Yoshida M, Murayama S, et al. Factors associated with bone thickness: comparison of the cranium and humerus. *PLoS One.* 2023;18(3):e0283636.
5. Barke M, Castro HM, Adesina OO, Chuang AZ, Do T, Patel RP, et al. Thinning of the skull base and calvarial thickness in patients with idiopathic intracranial hypertension. *J Neuroophthalmol.* 2022;42(2):192–198.
6. Rabbani CC, Patel JM, Nag A, Schueth E, Saltagi MZ, Kao R, et al. Association of intracranial hypertension with calvarial and skull base thinning. *Otol Neurotol.* 2019;40(6):e619–e626.
7. Rabbani C, Saltagi MZ, Ye MJ, Patel JM, Manchanda S, Nelson RF. Association of obstructive sleep apnea with calvarial and skull base thinning. *JAMA Otolaryngol Head Neck Surg.* 2018;144(6):513–518.
8. Moreira-Gonzalez A, Papay FE, Zins JE. Calvarial thickness and its relation to cranial bone harvest. *Plast Reconstr Surg.* 2006;117(6):1964–1971.
9. Rowbotham SK, Mole CG, Tieppo D, Blaszkowska M, Cordner SM, Blau S. Average thickness of the bones of the human neurocranium: development of reference measurements to assist with blunt force trauma interpretations. *Int J Legal Med.* 2023;137(1):195–213.
10. Baral P, Koirala S, Bajracharya S, Jha C, Banstola D, Shrestha R. Calvarial thickness of the Nepalese dry skulls. *J Inst Med Nepal.* 2015;37(3):89–96.
11. Hwang K, Kim JH, Baik SH. The thickness of the skull in Korean adults. *J Craniofac Surg.* 1999;10(5):395–399.
12. Sheaff M, Hopster D. Post mortem technique handbook. 2nd ed. London: Springer; 2005. p. 131–140.
13. Hwang K, Kim JH, Baik SH. Thickness map of parietal bone in Korean adults. *J Craniofac Surg.* 1997;8(3):208–212.
14. Bhattarai M. Radiological mapping of Nepalese calvaria. *J Nobel Med Coll.* 2013;2(1):31–35.
15. Ross MD, Lee KA, Castle WM. Skull thickness of Black and White races. *S Afr Med J.* 1976;50(16):635–638.
16. Adeloje A, Kattan KR, Silverman FN. Thickness of the normal skull in American Blacks and Whites. *Am J Phys Anthropol.* 1975;43(1):23–30.
17. Li H, Ruan J, Xie Z, Wang H, Liu W. Investigation of the critical geometric characteristics of living human skulls utilising medical image analysis techniques. *Int J Veh Saf.* 2007;2(4):345–357.
18. Pensler J, McCarthy JG. The calvarial donor site: an anatomic study in cadavers. *Plast Reconstr Surg.* 1985;75(5):648–651.
19. Lynnerup N, Astrup JG, Sejrsen B. Thickness of the human cranial diploe in relation to age, sex and general body build. *Head Face Med.* 2005;1(1):13.