

## Postoperative Endophthalmitis caused by *Escherichia coli* and *Burkholderia cepacia* Complex: A Rare Case Report

Ashwin Thakali, Ranju Kharel Sitaula, Pratap Karki, Aashish Raj Pant

### Author(s) affiliation

Department of Ophthalmology,  
Maharajgunj Medical Campus, B.P.  
Koirala Lions Centre for Ophthalmic  
Studies, Institute of Medicine,  
Kathmandu, Nepal

### Corresponding author

Ashwin Thakali, MBBS, MD  
thakaliashwin@gmail.com

### ABSTRACT

Endophthalmitis is one of the most serious complications following cataract surgery. Early treatment with intravitreal antibiotics with or without pars plana vitrectomy is the standard management but gram-negative bacteria and multi-drug resistant bacteria pose significant challenges as the prognosis is usually poor in such cases. We present a case of post-operative endophthalmitis following cataract surgery caused by multi-drug resistant *Escherichia coli* as well as *Burkholderia cepacia* complex. The patient was treated first with intravitreal antibiotics, then with core vitrectomy and intravitreal antibiotics. Intraocular lens explantation was also done at a later stage since there was no improvement.

### Keywords

*Burkholderia cepacia* complex; cataract surgery complications; *Escherichia coli*; post-operative endophthalmitis

### INTRODUCTION

Endophthalmitis is a medical emergency as delay in treatment may result in permanent vision loss.<sup>1</sup> A case series from Nepal showed growth of *Escherichia coli* in two out of eleven cases of endophthalmitis following cataract surgery.<sup>2</sup>

The *Burkholderia cepacia* complex (BCC) is a group of at least 20 closely related species of rare gram-negative, oxidase-positive, non-fermenting bacillary organisms.<sup>3</sup> Most of the case reports of BCC endophthalmitis reported poor visual outcomes that often result in phthisis, enucleation or visual acuity of light perception.<sup>4</sup>

We present a case of post cataract surgery endophthalmitis caused by antibiotic-resistant *E. coli* which in subsequent cultures showed growth of *Streptococcus pneumoniae* and *Burkholderia cepacia* complex, respectively. To the best of our knowledge, this is probably the first case report of endophthalmitis caused by BCC in Nepal.

### DOI

[10.59779/jiomnepal.1430](https://doi.org/10.59779/jiomnepal.1430)

### Submitted

Oct 31, 2025

### Accepted

Dec 10, 2025

## CASE PRESENTATION

A 69-year-old lady was referred to us from another hospital with a provisional diagnosis of Right Eye Postoperative Endophthalmitis. The patient had developed diminution of vision of the right eye on the second postoperative day of phacoemulsification cataract surgery and was referred to our center on the same day, 15<sup>th</sup> of February 2024. On examination, her best corrected visual acuity (BCVA) was 6/360. The cornea was slightly edematous with Descemet's Membrane folds and anterior chamber showed hypopyon of ~1 mm. On posterior segment examination, there was dense vitritis and disc was barely visible. Ultrasonography B scan showed hyperechoic shadows in the vitreous cavity which disappeared in low gain as shown in Fig. 1.

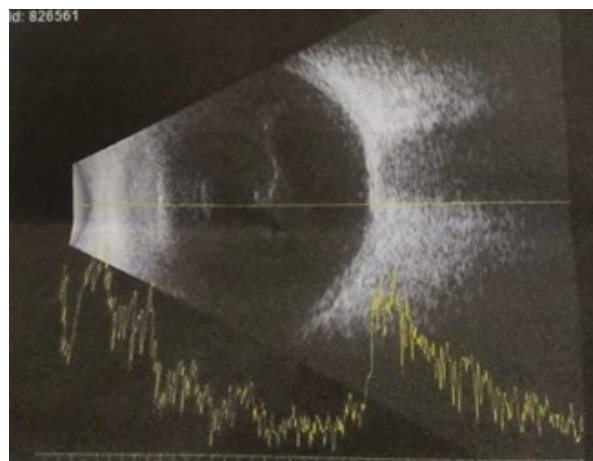
The patient immediately underwent vitreous tap for Gram stain and Culture and Sensitivity (c/s) followed by intravitreal injection Vancomycin 0.1 ml (1 mg) + Ceftazidime 0.1 ml (2.25 mg) and subconjunctival injection of Vancomycin 2 ml (10 mg) + Dexamethasone 0.5 ml (2 mg). The patient was also given topical Moxifloxacin and Prednisolone.

Culture and sensitivity report after 48 hours showed *E coli* sensitive to Chloramphenicol, intermediate sensitive to Levofloxacin and resistant to Amikacin, Ciprofloxacin, Ofloxacin, Moxifloxacin, Vancomycin and Gentamicin. On examination, BCVA was Hand Movement (HM), hypopyon was ~1.2 mm and the posterior pole was barely visible. So, we administered intravitreal injection of Levofloxacin 0.5 mg/0.1 ml and Dexamethasone 0.4 mg/0.1 ml on the same day and replaced Moxifloxacin eye drops with eye drop containing Chloramphenicol, Polymyxin B and Dexamethasone, and added Tab. Levofloxacin 750 mg OD for 2 weeks and Tab. Prednisolone 50 mg OD tapered over weeks.

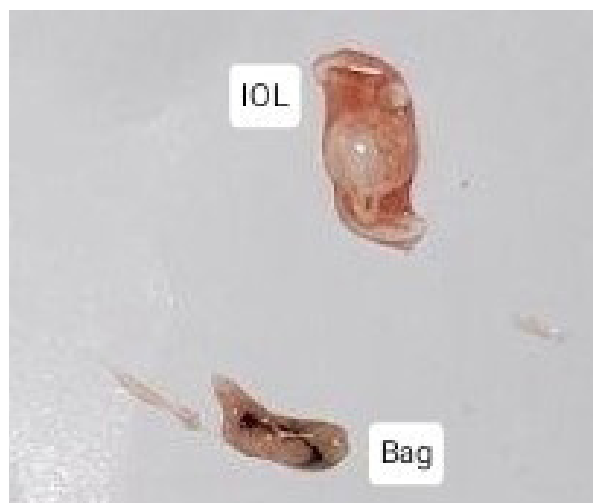However, there was no significant improvement over the next two days, and we performed RE core vitrectomy with intravitreal injection of Levofloxacin 0.25 mg/0.05 ml on 22<sup>nd</sup> February.

The patient was under regular follow up but was showing no signs of improvement and after 4 weeks, she was given another dose of intravitreal Levofloxacin and Dexamethasone; aqueous and vitreous tap was also done under topical anesthesia. Aqueous tap c/s showed *Streptococcus pneumoniae* sensitive to Chloramphenicol, Moxifloxacin, Levofloxacin and resistant to Amikacin and Cefazoline while vitreous c/s showed no growth. So, intravitreal Triamcinolone, Dexamethasone and Moxifloxacin, and intracameral Moxifloxacin was given and a repeat intravitreal dose was given 2 weeks later.

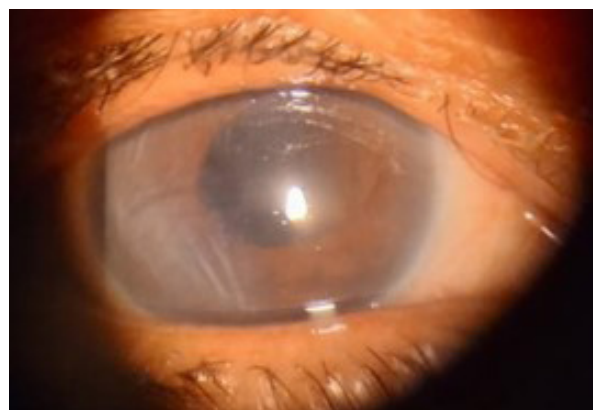Finally, after no major improvement in another two weeks of follow up, we performed Intraocular lens explantation via scleral tunnel on 26<sup>th</sup> April.



**Figure 1.** USG B-scan of right eye showing hyperechoic shadows in vitreous which disappeared in low gain, at presentation



**Figure 2.** Explanted IOL and capsular bag



**Figure 3.** Diffuse slit lamp illumination showing corneal edema with hazy view of iris

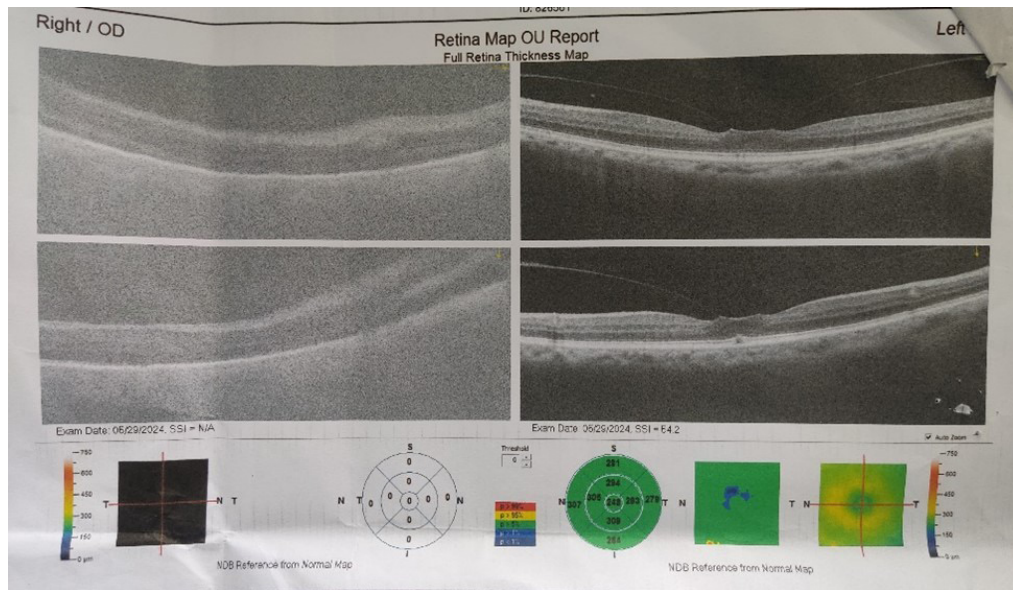


Figure 4. OCT showing shallow RD in right eye and vitreomacular traction in left eye

Intracameral Levofloxacin was also given and IOL and posterior capsular bag (Fig. 2) was sent for c/s. IOL c/s showed no growth while capsular bag c/s showed Burkholderia cepacia complex sensitive to chloramphenicol, cotrimoxazole, meropenem and ceftazidime. Thus, eyedrops containing Chloramphenicol, Polymyxin B and Dexamethasone was started 2 hourly along with 5% Sodium Chloride QID, Homatropine TDS and Ointment Chloramphenicol and Polymyxin B at bedtime.

Over the next month, the patient made slow but steady progress. On the last follow up, the patient’s BCVA was HM, and inflammatory activity was minimal. There was mild corneal edema and haziness, old keratic precipitates with minimal cellular activity in the anterior chamber as in Fig. 3.

The posterior pole was slightly visible and USG B-scan showed shallow retinal detachment which was consistent with OCT findings which also showed vitreomacular traction in left eye (Fig. 4,5). Retina consultation was done and owing to poor prognosis, no further intervention was done for the right eye and left eye was kept under observation for vitreomacular traction.

**DISCUSSION**

Bacterial endophthalmitis is commonly caused by gram-positive organisms, but gram-negative endophthalmitis are often associated with unfavorable visual acuity outcomes.<sup>5,6</sup> Among gram negative bacteria, Pseudomonas aeruginosa (34%) and Haemophilus influenzae (17%) are the common causative agents while Escherichia coli (3%) and Burkholderia cepacia complex (<0.1%) are both rare causes of endophthalmitis.<sup>7</sup> Following cataract surgery, endophthalmitis has been

reported in 0.1% of the cases.<sup>1</sup> Symptoms occur within 1 week postoperatively in 75% of cases, and include decreased vision (95%), red eye (80%), and eye pain (75%).<sup>3</sup> Our case presented on second postoperative day with all three symptoms and the growth on culture was Escherichia coli which was

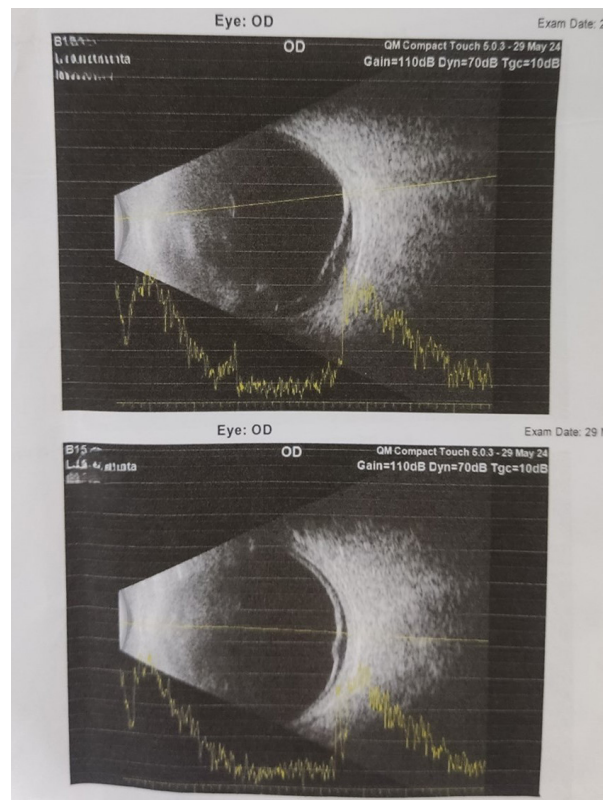


Figure 5. USG B-scan of right eye showing shallow RD and few hyperechoic shadows in vitreous disappearing in low gain

resistant to multiple antibiotics. Multi-drug resistant and extended-spectrum beta-lactamase (ESBL)-producing *E. coli* infection are difficult to treat and has shown to have a poor prognosis.<sup>8,9</sup> Our case also had an acute onset of symptoms, rapid progression and a prolonged course with minimal recovery of vision despite prompt action and an earlier-than indicated PPV.

Moreover, on repeat culture, our case showed *Burkholderia cepacia* complex. The first reported case of BCC endophthalmitis was successfully treated with subconjunctival piperacillin, intravitreal cefotaxime, and intravenous piperacillin and gentamicin.<sup>10</sup> However, most of the cases of endophthalmitis caused by *B. cepacia* had poor visual outcomes despite prompt treatment with appropriate antibiotics.<sup>7</sup> Our case also had a poor visual outcome despite earlier than indicated PPV and multiple doses of intravitreal antibiotics and at the last follow up, the patient had a visual acuity of HM with very gradual improvement in the clinical picture.

Also, on hindsight, since the organism was found to be residing on the capsular bag, we would like to propose capsular bag wash with antibiotics alongside PPV, or in cases not responding to conventional treatments, IOL explantation and capsular bag removal is required.

## CONCLUSION

Post-operative Endophthalmitis still remains the most dreaded complication after ophthalmic surgeries as multi-drug resistant cases like BCC are likely to have a poor outcome despite prompt and adequate management. Such cases may benefit from an early pars plana vitrectomy including cases with visual acuity better than HM. Chronic cases not responding to conventional treatment could have bacteria residing in the capsular bag. Our patient also required multiple interventions and despite intravitreal antibiotics, core vitrectomy as well as IOL explantation, we were unable to restore her vision.

Also, prevention is always better than cure, so extra preventive measures should be taken to avoid such events in the future.

## CONSENT

Verbal and written taken from patient and patient party

## ACKNOWLEDGEMENT

None

## FINANCIAL SUPPORT

The author(s) did not receive any financial support for the research and/or publication of this article.

## CONFLICT OF INTEREST

The author(s) declare that they do not have any conflicts of interest with respect to the research, authorship, and/or publication of this article.

## AUTHOR CONTRIBUTIONS

Ashwin Thakali is the main author responsible for conceptualization, resources, writing of the original draft, review and editing. Ranju Kharel was actively involved in conceptualization, resources, review, editing and supervision. Pratap Karki was the doctor primarily managing the case and helped with resources, review, editing as well as supervision. Aashish Raj Pant also helped with resources, review, editing and supervision.

## REFERENCES

1. Durand ML. Endophthalmitis. *Clin Microbiol Infect.* 2013;19(3):227–234. doi:10.1111/1469-0691.12118.
2. Gautam P, Joshi SN, Sharma A, et al. Outcome of patients with postoperative cluster endophthalmitis referred to a tertiary level eye care center in Nepal. *Nepal J Ophthalmol.* 2013;5(2):235–241. doi:10.3126/nepjoph.v5i2.8735.
3. Lipuma JJ. Update on the *Burkholderia cepacia* complex. *Curr Opin Pulm Med.* 2005;11(6):528–533. doi:10.1097/01.mcp.0000181475.85187.ed.
4. Beca FA, Sengillo JD, Robles-Holmes HK, et al. Endophthalmitis caused by *Burkholderia cepacia* complex (BCC): clinical characteristics, antibiotic susceptibilities, and treatment outcomes. *Res Sq.* 2023;rs.3.rs-3181158. doi:10.21203/rs.3.rs-3181158/v1.
5. Irvine WD, Flynn HW Jr, Miller D, et al. Endophthalmitis caused by gram-negative organisms. *Arch Ophthalmol.* 1992;110(10):1450–1454. doi:10.1001/archophth.1992.01080220112031.
6. Endophthalmitis Vitrectomy Study Group. Results of the Endophthalmitis Vitrectomy Study: a randomized trial of immediate vitrectomy and intravenous antibiotics for treatment of postoperative bacterial endophthalmitis. *Arch Ophthalmol.* 1995;113(12):1479–1496. doi:10.1001/archophth.1995.01100120009001.
7. Stevenson LJ, Dawkins RCH, Sheorey H, et al. Gram-negative endophthalmitis: a prospective study examining the microbiology, clinical associations and visual outcomes following infection. *Clin Exp Ophthalmol.* 2020;48(6):813–820. doi:10.1111/ceo.13768.
8. Dave VP, Pathengay A, Nishant K, et al. Clinical presentations, risk factors and outcomes of ceftazidime-resistant gram-negative endophthalmitis. *Clin Exp Ophthalmol.* 2017;45(3):254–260. doi:10.1111/ceo.12833.
9. Kim YC, Kim KS. A case of postoperative endophthalmitis by extended-spectrum beta-lactamase-producing *Escherichia coli*. *Korean J Ophthalmol.* 2012;26(4):306–308. doi:10.3341/kjo.2012.26.4.306.
10. Del Piero E, Pennett M, Leopold I. *Pseudomonas cepacia* endophthalmitis. *Ann Ophthalmol.* 1985;17(12):753–756.