

Diagnostic Hystero-Laparoscopy for Evaluation of Female Infertility: A Cross-sectional Study

Suvana Maskey, Jwala Thapa, Shree Prasad Adhikari, Nesuma Sedhain, Bhawani Silpakar

Author(s) affiliation

Department of infertility, Paropakar
Maternity and Women's Hospital,
Kupandole, Lalitpur, Nepal

Corresponding author

Suvana Maskey, MBBS, MD
suvanashrestha@yahoo.com

DOI

[10.59779/jiomnepal.1425](https://doi.org/10.59779/jiomnepal.1425)

Submitted

Oct 12, 2025

Accepted

Dec 9, 2025

ABSTRACT

Introduction

Diagnostic hystero-laparoscopy has additional advantage of direct visualization of pelvic pathology along with performing therapeutic surgery at same setting, compared to other diagnostic modalities. This study aims to determine the role of diagnostic hystero-laparoscopy in evaluation of infertile women.

Methods

This descriptive study was conducted from April to July 2025 including women presenting with infertility and planned for diagnostic hystero-laparoscopy in department of infertility at Paropakar Maternity and Women's Hospital. Any abnormalities detected during laparoscopy and hysteroscopy were recorded. If any therapeutic procedure was done, that was also noted. A structured proforma was used to collect data and descriptive analysis was done.

Results

During the study period 36 underwent diagnostic hystero-laparoscopy among which, 20 (55.55%) had primary infertility and 16 (44.44%) had secondary infertility. The mean age was 30.44 ± 4.70 years and the mean duration of infertility was 3.76 ± 3.71 years. The most common pathologies determined on hysteroscopy were uterine polyp and septate uterus, both being 6 in number (16.66%). On laparoscopy tubal block was noted in 22 (61.11%) women followed by pelvic adhesions which was seen in 19 (52.77%) cases. Most frequent therapeutic intervention done during laparoscopy was adhesiolysis (16, 44.44%) and during hysteroscopy were polypectomy and septal resection (6 each, 16.66%). Eleven women (30.55%) had undergone multiple procedures.

Conclusion

Tubal and peritoneal abnormalities were the two main factors determined on laparoscopy and most prevalent finding on hysteroscopy were uterine polyp and septate uterus. Adhesiolysis, polypectomy and septal resection were the main procedures performed.

Keywords

Hysteroscopy; infertility; laparoscopy; tubal block; uterine factor

INTRODUCTION

Infertility is defined as the inability to conceive after 12 months of regular, unprotected intercourse. Its overall prevalence varies depending upon the population and is estimated to be 10-15% among reproductive age couples worldwide.¹ In developing countries the average prevalence is estimated to be around 6.9-9.3%, however the exact prevalence of Nepal is still unknown.² The main causes of infertility include male factor (20%), ovulatory disorders (30-40%), tubal and peritoneal factors (30-40%), cervical factors (5%), uterine factor (15%) and unexplained infertility (10%).³

Traditional diagnostic approaches such as hysterosalpingography (HSG), ultrasonography (USG) may not always reveal underlying abnormalities, necessitating advanced diagnostic tools. In a study done by Yildirim et al tubo-peritoneal disease was detected in 55.8% of the cases including adhesion in 29.8%, endometriosis in 9% and mixed pathology in 16.9% during laparoscopy done to the cases evaluated as normal in HSG.⁴ Furthermore, HSG has low specificity in the determination of uterine pathologies, hence intrauterine evaluation with hysteroscopy is beneficial.^{4,5} Diagnostic hystero-laparoscopy (DHL) enables detailed, direct visualization and determination of tubal morphology and patency, uterine, ovarian, and adnexal pathology, along with visualization of the uterine cavity and endometrium.⁴ Moreover, it has added benefit of therapeutic interventions that can be performed at the same setting.

Though there are many studies on evaluating the role of DHL in infertility, studies done in Nepal are limited. Hence this study aims to determine the role of DHL in evaluation of infertile women and to know therapeutic interventions done.

METHODS

This was a descriptive cross-sectional study including all women presenting with infertility and planned for DHL during the study period from April to July 2025, conducted in the Department of infertility at Paropakar Maternity and Women's Hospital, Kupandole, Lalitpur, Nepal. Ethical clearance was taken from the Institutional Review Committee of National Academy of Medical Sciences (NAMS) with Reference Number 1470/2081/82.

Detailed history was taken from the women with the complain of failure to conceive for a period of one year or more. Blood investigations, basic endocrinological investigations, USG, HSG and semen analysis were done. Those women planned for DHL for abnormal HSG and USG findings like unilateral or bilateral tubal block, hydrosalpinx, uterine cavity abnormalities were included after taking informed written consent. Women with

history of medical disorders with contraindication for anaesthesia, active pelvic infection, lower genital tract malignancy, suspected pregnancy and those who refused surgery were excluded from study.

Informations on the patient's age, infertility duration, type of infertility and body mass index (BMI) were recorded in pre-designed structured proforma. DHL was performed in proliferative phase between 9 and 12 days of the menstrual cycle. On hysteroscopy, any abnormalities in cervical canal, endometrium, fundus, presence and calibre of both ostia were noted. During laparoscopic supra umbilical 10mm primary port was made for abdominal entry and 5mm secondary ports were made, 1 to 3 in number, depending upon the pelvic pathology. Systematic visualization of the pelvis beginning from the uterus, anterior and posterior surface of uterus, uterosacral ligaments, ovaries, peritoneal surface was done and any abnormality such as uterine anomalies, fibroid uterus, polycystic ovaries, ovarian cyst, endometriosis, pelvic/adnexal adhesions were noted. The fallopian tubes were examined from its distal to proximal segment for signs of distal tubal occlusion or fimbrial phimosis, or hydrosalpinx. Chromopertubation (CPT) done and any spillage of the dye was noted. If no spillage seen, side of tubal block if unilateral or bilateral tubal block was recorded. Therapeutic intervention if done during the procedure was also noted.

A structured proforma was used to collect the data. The statistical analysis was done using SPSS version 23. The descriptive statistical analysis was done. Frequency and percentages were calculated for binary data whereas mean and standard deviation were calculated for continuous data.

RESULTS

During the study period of 3 months duration, 36 women underwent DHL for infertility with various indications such as HSG finding of bilateral tubal block in 21 cases and unilateral tubal block in 10 cases. Only 5 patients had both tubes patent, but DHL was done for other indications such as suspected uterine septum, uterine adhesions on HSG.

The general characteristics of study population is shown in Table 1. Among the study population, primary infertility was more common than secondary infertility. The women's age ranged from 22 to 40 years, and majority of women (14, 38.88%) belonged to 26 to 30 years age group. Most of the women (22, 61.11%) presented with duration of infertility less than 5 years, followed by duration in between 5 to 10 years. Only 1 woman (2.77%) was trying for conception for more than 10 years. Among the study population 20 (55.55%) women had normal BMI, and the mean BMI was $24.73 \pm 3.84 \text{ kg/m}^2$.

Table 1. General characteristics of infertile women undergoing diagnostic hystero-laparoscopy

Variable	Frequency (%)	Mean ± S.D.
Age group		
20-25	5(13.88)	30.44 ± 4.7
26-30	14(38.88)	
31-35	11(30.55)	
35-40	6(16.66)	
BMI		
<18.5 kg/m ²	1(2.77)	24.73 ± 3.8
18.5 to <25 kg/m ²	20(55.55)	
25 to < 30kg/m ²	11(30.55)	
>30 kg/m ²	4(11.11)	
Infertility Duration		
< 5 years	22(61.11)	3.76 ± 3.7
5-10 years	13(36.11)	
>10 years	1(2.77)	
Type of Infertility		
Primary Infertility	20(55.55)	
Secondary Infertility	16(44.44)	

On hysteroscopy 18 (50%) patients had normal findings. The commonest pathologies noted were uterine polyp and septate uterus, both being 6 in number (16.66%). Other findings were synechiae, ostial adhesion and narrowed uterine cavity (Figure 1).

On laparoscopy, 13 (36.11%) patients had normal finding, and the most common pathology was tubal block (22, 61.11%), followed by pelvic adhesions (19, 52.77%). Other findings were hydrosalpinx,

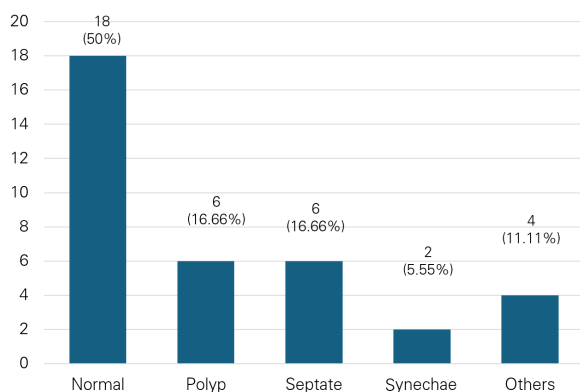


Figure 1. Hysteroscopy findings of diagnostic hystero-laparoscopy

Table 2. Therapeutic interventions done during diagnostic hystero-laparoscopy

Therapeutic Procedure	Number (%)
Laparoscopic Procedure	
Adhesiolysis	16(44.44)
Tubal reconstruction	6(16.66)
Bilateral salpingectomy	5(13.88)
Ovarian cystectomy	2(5.55)
Ovarian drilling	1(2.77)
Hysteroscopic Procedure	
Septal resection	6(16.66)
Polypectomy	6(16.66)
Adhesiolysis	2(5.55)
Lateral metroplasty	1(2.77)
Tubal canulation	1(2.77)
Others	2(5.55)
Multiple Procedures	11(30.55)

endometriosis, fibroid, and polycystic ovaries (Figure 2). More than one finding was present in 16 patients. Nine women with bilateral tubal block on HSG had patent tube on CPT, bilateral patent in 6 and unilateral patent in 3 women. Four women with unilateral tubal block on HSG had patent tube on CPT during laparoscopy.

During laparoscopy adhesiolysis was the main therapeutic intervention done in 16 patients (44.44%) followed by tubal reconstruction such as tubal canulation and neosalpingostomy, done in 6 patients (16.66%). During hysteroscopy most frequent procedures were septal resection and polypectomy, both 6 (16.66%) in number. Eleven women (30.55%) had undergone multiple

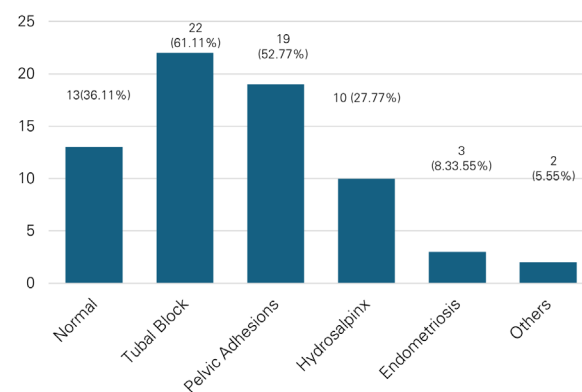


Figure 2. Laparoscopy findings of diagnostic hystero-laparoscopy

procedures (table 2). There was no major surgical or anaesthetic complication in any of the patients.

DISCUSSION

Infertility affects a large proportion of the global population, with approximately one in six people experiencing it in their lifetimes.⁶ Among female factor infertility, the most common cause is tubo-peritoneal pathology accounting for 30%–35% cases, followed by ovulatory dysfunction (20%–30%) and uterine pathology (15%).⁷ The gold standard method for diagnosing tubo-peritoneal pathology is laparoscopy. In addition, it allows determination of uterine as well as ovarian pathology. Furthermore, hysteroscopy in conjunction with laparoscopy helps in the evaluation of endocervical canal, uterine cavity, endometrium, and tubal ostia. Fertility success rates are also higher when laparoscopy is combined with diagnostic or surgical hysteroscopy.⁸ Hence DHL has been considered as essential diagnostic as well as therapeutic modality for management of infertility.

In present study 36 women underwent diagnostic hystero-laparoscopy among which primary infertility (20, 55.55%) was seen more than secondary infertility (16, 44.44%) aligning with findings of other studies.^{5,7,9} Majority of women belonged to 26 to 30 years age group, which supports the trend of early marriage and childbearing in developing countries compared to developed countries. Similar age group patients were observed in other studies.^{5,9,10} The mean age was 30.44 ± 4.70 years closely corresponding to the mean age reported by Bano et al and Singh et al.^{11,12} Among the study population normal BMI was predominant (20, 55.55%), finding comparable to other studies (57.8%).^{1,13} Most of the women presented with duration of infertility less than 5 years, finding similar to other studies.¹⁰

Tubo-peritoneal pathologies were two main abnormalities identified in infertile patients across various studies. In a study done by Anusha et al the most prevalent abnormalities seen during laparoscopy in both the primary and secondary infertility were adnexal adhesion (21.33%) and hydrosalpinx (15.33%).¹⁴ Furthermore Madhavi et al also determined adnexal adhesion (65; 21.7%) and hydrosalpinx (46; 15.3%), as the most common abnormalities which was consistent with the findings from other studies.^{1,7} In the present study also tubal and peritoneal disorder were most prevalent findings which were determined in 61.11% and 52.77% of women respectively but these figures were higher compared to above mentioned studies. Selection of participants for DHL who were already diagnosed to have tubal pathology on HSG could be the reason for this finding. Comparable to our finding higher proportion of tubal and peritoneal pathologies were reported by Selvaraj et al (68.46%

and 42.3% respectively) and Subedi et al (62% and 63% respectively) which can be explained by both studies having similar selection criteria, such as abnormal HSG findings, as ours.^{2,9} These findings reveal that tubal factor infertility is the foremost reason of female infertility, the majority of which is due to PID (pelvic inflammatory disease). Other than PID, endometriosis, tuberculosis, previous surgeries are also responsible for tubal damage and pelvic adhesions. However, Bansal and Bano et al had determined ovarian factors like PCOS, endometrioma, ovarian cysts as the most common abnormality (62.2% and 30% respectively).^{11,13}

Laparoscopic abnormalities were more prevalent than the hysteroscopic abnormalities in current as well as majority of other studies. Uterine pathologies are the cause of infertility in as many as 15% of couples seeking treatment.¹⁵ The uterine disorders most often observed during hysteroscopy are septae, polyps, synechiae, submucous myomas, adenomyosis, endometritis, lesions of utero-tubal junction and anomalies of cervical canal.¹⁶ In present study most prevalent hysteroscopic abnormalities were uterine polyp and septate uterus (6, 16.66% each). Studies have reported septate uterus as most prominent finding on hysteroscopy.^{9,15,17,18} The prevalence of uterine anomaly in infertility patient is 4-8%, the foremost reason being septate uterus.⁸ Although a diagnosis of septate uterus per se is not an indication for septoplasty, the reproductive performance of women with an uncorrected septum is rather poor.¹⁵ Hysteroscopic septum incision is associated with improved clinical pregnancy rates in women with infertility hence it is reasonable to consider septum incision.¹⁹ The incidence of asymptomatic endometrial polyps in women with infertility has been reported to range from 10% to 32%.¹⁵ The presence of polyp may hinder implantation and cause infertility. A systematic review, which included 8 studies with 2267 patients, showed that hysteroscopic resection for endometrial polyps with an average diameter of less than 2 cm was correlated with a higher pregnancy rate after intrauterine insemination.⁸ Bansal has determined uterine polyp as the commonest finding consistent to present study.¹¹ Besides uterine septum and polyp other studies have noted uterine synechiae as prevalent finding in their studies.^{1,7}

Most prevalent therapeutic intervention done during laparoscopy was adhesiolysis (16, 44.44%) which should be obvious as tubal disease and peritoneal adhesions were the major findings during laparoscopy requiring correction with adhesiolysis. Patel et al also reported laparoscopic adhesiolysis (36.8%) as most common therapeutic surgery done.⁷ On contrary ovarian drilling was most frequently performed procedure in other studies.¹⁷ During hysteroscopy septal resection and

polypectomy were two main procedures (6, 16.66% each) in current study. Most frequent hysteroscopic procedure done was polypectomy in a study done by Nayak et al whereas it was septal resection in a study done by Selvaraj et al.^{15,17} While Patel et al had performed hysteroscopic polypectomy, myomectomy and septal resection in similar no of patients.⁷

This study was single centred with small study population so detailed sub categorical analysis comparing primary and secondary infertility could not be done. Further larger and multicentric study will help in detail assessment of factors affecting infertility according to type of infertility and pattern of therapeutic interventions done during DHL.

CONCLUSION

Tubal and peritoneal abnormalities are the two main factors determined on laparoscopy. Laparoscopic abnormalities were more prevalent than hysteroscopic abnormalities and most prevalent finding on hysteroscopy was uterine polyp and septum. Laparoscopic adhesiolysis, hysteroscopic polypectomy and septal resection were the main procedures performed in this study. Hence diagnostic hystero-laparoscopy is crucial, advanced diagnostic modality that helps in determining underlying pathology, performing fertility enhancing surgery as well as further planning of infertility management.

ACKNOWLEDGEMENT

None

FINANCIAL SUPPORT

The author(s) did not receive any financial support for the research and/or publication of this article.

CONFLICT OF INTEREST

The author(s) declare that they do not have any conflicts of interest with respect to the research, authorship, and/or publication of this article.

REFERENCES

1. Chanu SM, Rudra Pal GS, Panda S, et al. Diagnostic hysteroscopy for evaluation of infertility: our experience in a tertiary care hospital. *J Hum Reprod Sci.* 2018;11(1):19-23. DOI: 10.4103/jhrs.JHRS_114-16
2. Subedi SS, Bhansakarya R, Shrestha P, et al. Outcome of laparoscopy in infertile couples attending a teaching hospital in Eastern Nepal: a descriptive cross-sectional study. *J Nepal Med Assoc.* 2020;58(231):889-892. DOI: 10.31729/jnma.5542
3. Thimmappa SS, Datti SN. Diagnostic laparoscopy in evaluation of female subfertility factors: experience in rural medical college. *Int J Contemp Med Res.* 2020;7(3). DOI: 10.21276/ijcmr.2020.7.3.2
4. Muradiye Y, Yanik A. Comparison of hysterosalpingography diagnostic value with laparoscopy and hysteroscopy findings in infertility research. *Ann Med Res.* 2023;30(6):1. DOI: 10.5455/annalsmedres.2023.03.073
5. Datti SN, K S, Venkatesh S, et al. Evaluation of infertile women by diagnostic hysteroscopy. *New Indian J OBGYN.* 2022;8(2):295-298. DOI: 10.21276/obgyn.2022.8.2.26
6. World Health Organization. Infertility prevalence estimates, 1990–2021. Geneva: World Health Organization; 2023.
7. Patel AJ, Vaghela Z, Patel A, et al. Diagnostic hysteroscopy for evaluation of infertility: our experience in a tertiary care hospital (a study of 70 cases). *Int J Pharm Clin Res.* 2024;16(8):165-169. DOI: 10.25258/ijpcr.2024.16.8.165
8. Varlas V, Rhazi Y, Cloțea E, et al. Hysteroscopy: a gold standard for diagnosing and treating infertility and benign uterine pathology. *J Clin Med.* 2021;10(16):3749. DOI: 10.3390/jcm10163749
9. Nanaware SS, Saswade M, Shende PN, et al. Role of hysteroscopy in the evaluation of female infertility in tertiary care centre. *Int J Contemp Med Res.* 2016;3(10):3063-3065.
10. Gambhava N, Singh K, Modi M, et al. Role of diagnostic hysteroscopy in the evaluation of infertility among patients attending a tertiary care center of Ahmedabad, Gujarat. *Natl J Physiol Pharm Pharmacol.* 2022;12. DOI: 10.5455/njppp.2022.12.073220227082022
11. Bano A, Sneha P. Role of diagnostic hysteroscopy in the evaluation of infertility: a prospective study from Telangana, India. *J Evol Med Dent Sci.* 2021;10(32):2640-2644. DOI: 10.14260/jemds/2021/540
12. Singh N, Pramanik KD, Bajaj M, et al. Diagnostic hysteroscopy: an important tool in evaluation of female infertility in beneficiaries of ESI scheme in Eastern India. *Asian J Med Sci.* 2022;13(5):183-188. DOI: 10.3126/ajms.v13i5.44227
13. Bansal V, Gilhotra S, Bhavani BH, et al. To study the role of diagnostic hysteroscopy in the evaluation of infertility. *Int J Clin Obstet Gynaecol.* 2023;7(6):27-34. DOI: 10.33545/gynae.2023.v7.i6a.1395
14. Anusha M, Katti K, Subbarayappa N. An observational study of diagnostic hysteroscopy for evaluation of infertility at a tertiary care hospital. *Indian J Obstet Gynecol Res.* 2024;11(4):553-557. DOI: 10.18231/ijog.2024.099
15. Nayak PK, Mahapatra PC, Mallick J, et al. Role of diagnostic hysteroscopy in the evaluation of infertility: a retrospective study of 300 patients. *J Hum Reprod Sci.* 2013;6(1):32-34. DOI: 10.4103/0974-1208.112378
16. Shanmugham D, Sahitya ND, Natarajan S, et al. Role of diagnostic hysteroscopy in the evaluation of female infertility. *Int J Reprod Contracept Obstet Gynecol.* 2019;8(8):3156-3160. DOI: 10.18203/2320-1770.ijrcog20193528
17. Selvaraj P, Parpillewar M, Fidvi J. Diagnostic hysteroscopy in the evaluation of female factor infertility: a cross-sectional study at a tertiary care hospital in Central India. *Int J Infertil Fetal Med.* 2020;11(2):37-41.

18. Mehta AV, Modi AP, Raval BM, et al. Role of diagnostic hysterolaparoscopy in the evaluation of infertility. *Int J Reprod Contracept Obstet Gynecol.* 2016;5(2):437-440. DOI: 10.18203/2320-1770.ijrcog20160385
19. Madhuri N, Rashmi HS, Sujatha MS, et al. Role of diagnostic hysterolaparoscopy in the evaluation of female infertility. *Int J Res Med Sci.* 2019;7(5):1531-1535. DOI: 10.18203/2320-6012.ijrms20191630