

## Managing a Rare Major Aortopulmonary Collaterals with Single Ventricle Physiology through Coiling and Cavopulmonary Shunt in a Single Hybrid Setting: A Case Report

Samir Kumar Yadav, Anil Bhattarai, Ravi Baral, Prabhat Khakural

### Author(s) affiliation

Department of Cardiovascular & Thoracic Surgery, Maharajgunj Medical Campus, Manmohan Cardiothoracic Vascular and Transplant Centre, Institute of Medicine, Kathmandu, Nepal

### Corresponding author

Anil Bhattarai, MS, MCh  
anbh10000@gmail.com

### ABSTRACT

We report a case of a 15-year-old female with single ventricle physiology, double outlet right ventricle, situs inversus, and major aortopulmonary collateral arteries (MAPCAs), treated in a single hybrid setting with endovascular coiling of nonessential MAPCAs and Bidirectional Glenn (BDG) procedure. Current guidelines recommend optimizing the pulmonary vascular bed through unifocalization of essential MAPCAs and embolization of nonessential MAPCAs to achieve Cavo pulmonary anastomosis, often via single- or multi-staged approaches. This case demonstrates the feasibility of a hybrid approach for complex CHDs.

### Keywords

Double outlet right ventricle; single ventricle physiology; major aortopulmonary collateral arteries; Bidirectional Glenn procedure

### DOI

[10.59779/jiomnepal.1364](https://doi.org/10.59779/jiomnepal.1364)

### Submitted

Feb 13, 2025

### Accepted

Nov 28, 2025

### INTRODUCTION

Double Outlet Right Ventricle (DORV), characterized by both great arteries arising from the right ventricle, is typically associated with ventricular septal defect (VSD) or atrioventricular septal defect (AVSD) and other cardiac malformations.<sup>1</sup> Major Aortopulmonary Collateral Arteries (MAPCAs) are rare in CHDs, most commonly seen in PA/VSD or Tetralogy of Fallot (TOF).<sup>2</sup> The Bidirectional Glenn (BDG) procedure, a superior Cavo pulmonary anastomosis, is a standard intervention for patients with anatomic or functional single ventricle physiology.<sup>3</sup> This report presents a 15-year-old female with SVP, DORV, situs inversus, and MAPCAs, managed with endovascular coiling and BDG in a single hybrid setting.

## CASE PRESENTATION

A 15-year-old female with known situs inversus presented with exertional dyspnea and palpitations. Clinical examination revealed central cyanosis, clubbing, and oxygen saturation of 88–90% in room air. Pre-operative echocardiography demonstrated dextrocardia, SVP, DORV, a large inlet VSD, MAPCAs to the left pulmonary arteries, severe pulmonary stenosis, bilateral confluent pulmonary arteries, and severe tricuspid regurgitation. Cardiac catheterization confirmed a mean pulmonary artery pressure (MPAP) of 12 mmHg, pulmonary vascular resistance index (PVRI) of 0.01, bilateral confluent pulmonary arteries (left: 13 mm; right: 14 mm), a single significant MAPCA (4 mm) from the descending thoracic aorta, and a McGoon ratio of 1.9.

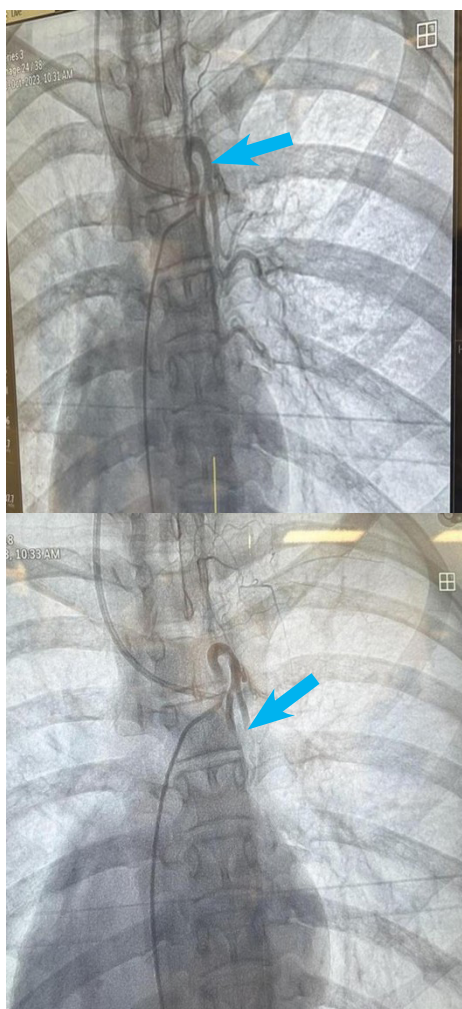
The patient underwent a hybrid procedure combining endovascular coiling of the MAPCA (Figure 1) and BDG without CPB. The BDG was performed via median sternotomy, with Veno atrial

cannulation, superior vena cava (SVC) division, and end-to-side anastomosis to the right pulmonary artery. Post-procedure pressures were verified.

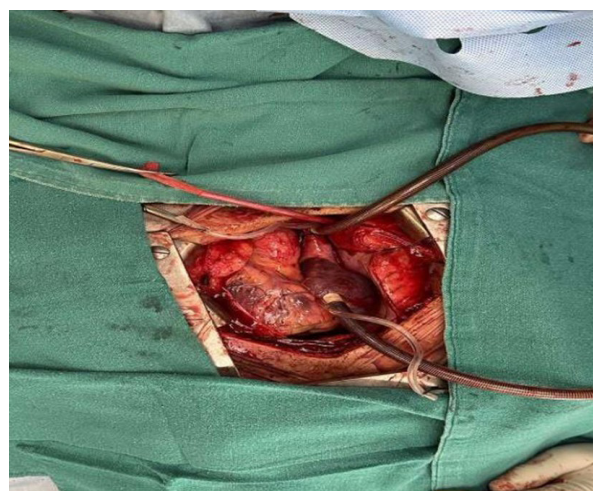
On the operative day, reoperation was required due to suspected reactionary hemorrhage, evidenced by high drain output, hemodynamic instability, and increasing inotropic support. Approximately 350 mL of blood clot was removed, and an arterial jet from the right sternal edge was cauterized. On the first postoperative day, the patient experienced atrial fibrillation, treated with intravenous amiodarone, followed by oral maintenance dosing after sinus rhythm restoration. The remainder of the hospital stay and one-month follow-up were uneventful.

## DISCUSSION

DORV accounts for 1–3% of CHDs, with a prevalence of 3–9 per 100,000 live births.<sup>1,4</sup> In PA/VSD, unifocalization of essential MAPCAs and intracardiac repair are standard, while embolization of nonessential MAPCAs promotes intrapericardial pulmonary artery growth and prevents hypoperfusion syndrome post-CPB.<sup>5,6</sup> However, MAPCA management in SVP is rarely reported.<sup>5</sup> Limited studies describe single-stage unifocalization with BDG in SVP, with better outcomes in patients achieving Cavo pulmonary anastomosis compared to those who do not.<sup>5,7,8</sup> Optimizing the pulmonary vascular bed is critical for successful Cavo pulmonary anastomosis in SVP with MAPCAs.<sup>4,5</sup> The BDG procedure has a mortality rate of less than 2%, with complications (e.g., emergency catheterization, neurologic deficits, reoperation) occurring in approximately 30% of cases.<sup>3</sup> This case highlights the efficacy of a hybrid approach combining endovascular and surgical techniques for complex CHDs



**Figure 1.** Intra-operative catheterization showing a single MAPCA from the descending thoracic aorta (A) and post-embolization coiling (B).



**Figure 2.** Intra-operative image of the BDG procedure without cardiopulmonary bypass (CPB), with Veno atrial cannulation

## CONCLUSION

While MAPCA management in PA/VSD is well-established, its application in SVP requires further exploration. This case underscores the potential of hybrid procedures to optimize outcomes. Further studies on long-term outcomes are needed to guide management.

## CONSENT

Written informed consent was taken from the patient regarding the case publication.

## FINANCIAL SUPPORT

The author(s) did not receive any financial support for the research and/or publication of this article.

## CONFLICT OF INTEREST

None

## REFERENCES

1. Bell-Cheddar Y, Devine WA, Diaz-Castrillon CE, et al. Double outlet right ventricle. *Front Pediatr.* 2023;11:1087290. doi:10.3389/fped.2023.1087290

2. Patrick WL, Mainwaring RD, Reinhartz O, et al. Major aortopulmonary collateral arteries with anatomy other than pulmonary atresia/ventricular septal defect. *Ann Thorac Surg.* 2017;104(3):907–916. doi:10.1016/j.athoracsur.2017.02.029
3. Salik I, Mehta B, Ambati S. Bidirectional Glenn procedure or hemi-Fontan. In: *StatPearls.* Treasure Island (FL): StatPearls Publishing; 2024. Available from: <https://www.ncbi.nlm.nih.gov/books/NBK563299/>
4. Obler D, Juraszek AL, Smoot LB, et al. Double outlet right ventricle: aetiologies and associations. *J Med Genet.* 2008;45(8):481–497. doi:10.1136/jmg.2008.057984
5. Reinhartz O, Reddy VM, Petrossian E, et al. Unifocalization of major aortopulmonary collaterals in single-ventricle patients. *Ann Thorac Surg.* 2006;82(3):934–939. doi:10.1016/j.athoracsur.2006.03.063
6. Alex A, Ayyappan A, Valakkada J, et al. Major aortopulmonary collateral arteries. *Radiol Cardiothorac Imaging.* 2022;4(1):e210157. doi:10.1148/ryct.210157
7. Bhende VV, Majmudar HP, Sharma TS, et al. Concomitant single-stage unifocalization and cavopulmonary anastomosis in an adolescent with univentricular physiology and major aortopulmonary collateral arteries. *Cureus.* 2021;13(12):e20171. doi:10.7759/cureus.20171
8. Sandica E, Beck C, Kececioglu D, et al. Concomitant one-stage unifocalization and bidirectional Glenn procedure. *Pediatr Cardiol.* 2011;32(2):224–226. doi:10.1007/s00246-010-9850-0