

Thoracic Segmental Spinal Anesthesia for Laparoscopic Cholecystectomy: A Case Report

Nitendra Raj Bajracharya¹, Pankaj Joshi¹, Biplov Neupane¹, Reshma Shrestha¹, Milan KC², Prashant Bhatta¹, Bashudev Parajuli¹

Author(s) affiliation

¹Department of Anesthesiology, Maharajgunj Medical Campus, Tribhuvan University Teaching Hospital, Institute of Medicine, Maharajgunj, Kathmandu, Nepal

²Department of General Surgery, Maharajgunj Medical Campus, Tribhuvan University Teaching Hospital, Institute of Medicine, Maharajgunj, Kathmandu, Nepal

Corresponding author

Nitendra Raj Bajracharya, MBBS
ntnbajra@gmail.com

ABSTRACT

Laparoscopic surgery is normally performed under general anesthesia. Thoracic segmental spinal anesthesia (TSSA) can be a suitable alternative to general anesthesia for patients with respiratory diseases, as it avoids the risk of general anesthesia. We successfully managed a 74-year-old lady with COPD undergoing elective laparoscopic cholecystectomy with TSSA at T8-T9 interspace using 1.7 ml of hyperbaric bupivacaine 0.5% with 0.3 ml (15mcg) of fentanyl. Some discomfort was managed with 1mg midazolam and 50 mcg fentanyl intravenously. There was no neurological deficit and major hemodynamic fluctuations intra and post-operatively and recovery was uneventful.

Keywords

COPD, laparoscopic cholecystectomy, thoracic segmental spinal anesthesia

DOI

[10.59779/jiomnepal.1315](https://doi.org/10.59779/jiomnepal.1315)

Submitted

Jan 9, 2024

Accepted

Mar 20, 2024

INTRODUCTION

Laparoscopic cholecystectomy is normally performed under general anesthesia (GA). When there are contraindications to GA or GA poses high risk, then the central neuraxial block (CNB) can be considered to be an alternative. Previously, lumbar spinal anesthesia with thoracic epidural were considered for CNB. Currently, single-shot thoracic segmental spinal anesthesia is gaining popularity in similar situations.^{1,2}

Here, we present a case of successful management of laparoscopic cholecystectomy under thoracic segmental spinal anesthesia.

CASE PRESENTATION

A 74-year-old, 50 kg female presented with signs and symptoms of symptomatic cholelithiasis, hence planned for laparoscopic cholecystectomy. She was known to have chronic obstructive pulmonary

INTRODUCTION

Laparoscopic cholecystectomy is normally performed under general anesthesia (GA). When there are contraindications to GA or GA poses high risk, then the central neuraxial block (CNB) can be considered to be an alternative. Previously, lumbar spinal anesthesia with thoracic epidural were considered for CNB. Currently, single-shot thoracic segmental spinal anesthesia is gaining popularity in similar situations.^{1,2}

Here, we present a case of successful management of laparoscopic cholecystectomy under thoracic segmental spinal anesthesia.

CASE PRESENTATION

A 74-year-old, 50 kg female presented with signs and symptoms of symptomatic cholelithiasis, hence planned for laparoscopic cholecystectomy. She was known to have chronic obstructive pulmonary disease (COPD) for 12 years, undertaking Rotacap Fluticasone and Tiotropium regularly and Tab Doxofylline 400mg which was recently stopped after consulting her physician. Her oxygen saturation was 87% with decreased air entry bilaterally with occasional wheezing on auscultation. Chest X-ray revealed hyperinflated lung fields. Her exercise tolerance was limited, and she felt shortness of breath on moving few steps upwards [Metabolic Equivalent of Task (METS)<4 with New York Health Association (NYHA) II]. Her Pulmonary Function Test showed moderate airflow obstruction with Forced Expiratory Volume in first second (FEV1) 0.71. Her echocardiography revealed mild Mitral Regurgitation, mild Tricuspid Regurgitation, normal chambers, no evidence of pulmonary hypertension

with Grade-I LVDD with Normal LVEF 60%. Her ABG was normal. Her vitals and other systematic findings were within limits. She was a non-smoker and had no allergic history. Baseline Hemoglobin was 11.5 gm% and other investigations were within normal limits.

She was fasted as per our institution's protocol, counseled, and consented for thoracic segmental spinal anesthesia. In the Operation room, baseline vitals revealed similar pre-operative findings. Almost 200 ml of Ringer's Lactate (RL) was preloaded via 18G functional IV cannula. In sitting position, Ultrasound of spine was considered, using a curvilinear probe and intervertebral space T8-T9 was marked. After taking all the aseptic precautions, skin was infiltrated with 2 ml of 2% Lignocaine at the same level and Spinal anesthesia was initiated using 25G Quincke Needle in the same space via midline approach. After confirmation of CSF flow, 1.7ml of 0.5% Hyperbaric Bupivacaine with 0.3ml of 15 mcg Fentanyl was then administered. The patient was kept in supine position. Sensory block level of T2 to L3 and Modified Bromage score of M2 was achieved. Oxygen was supplemented via Face mask at 5 L/min and her saturation was above 95% throughout surgery. Ceftriaxone 1 gm was administered as antibiotic prophylaxis.

Surgery was commenced by creating pneumoperitoneum and intra-abdominal pressure was maintained at 10 mm of Hg. After a few minutes, she complained of nausea and was restless. Midazolam 1mg and Fentanyl 50mcg were supplemented intravenously. She received Ondansetron 4mg, Dexamethasone 8 mg and Paracetamol 1 gm intraoperatively. The total

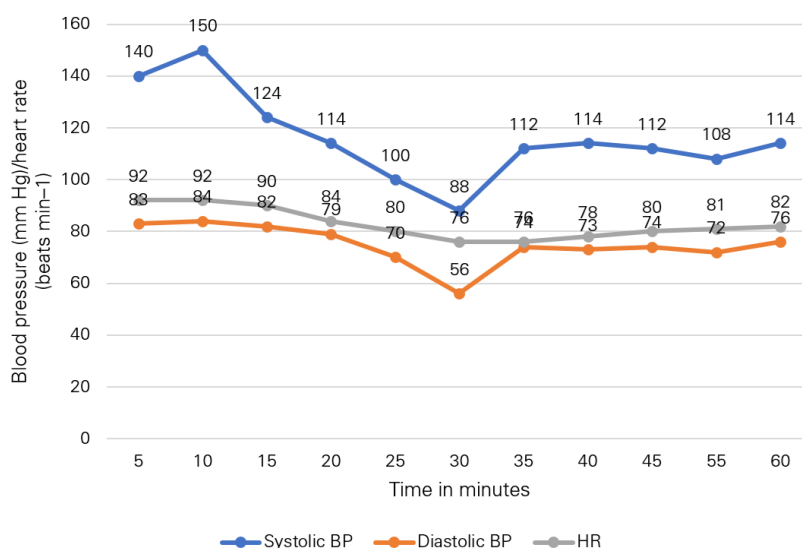


Figure 1. Intraoperative hemodynamics

duration of surgery was 40 minutes and there was one episode of hypotension (figure 1) that was managed with Mephentermine 6 mg bolus. She was then transferred to Post anesthesia care unit (PACU) for 2 hours and was transferred to the ward.

The post-operative period was uneventful. Oral diet was started after 6 hours, and the patient was discharged home on the first postoperative day with oral antibiotics and Paracetamol.

DISCUSSION

Unlike open surgery, this procedure requires very small incisions and is beneficial in lessening pain, shorter hospital stay and swift return to daily life due to less tissue damage and fast recovery.⁴

Laparoscopic cholecystectomy is classically performed under GA. However, GA poses a risk in patients with cardiopulmonary diseases. Patients with Chronic obstructive pulmonary disease (COPD) have a high risk for postoperative morbidity and mortality,^{5,6} and it is associated with prolonged mechanical ventilation after surgery⁷ which can result in ventilator-induced lung injury and pulmonary infections.⁸ Therefore, segmental thoracic spinal anesthesia can be a beneficial alternative in these patients.

Nonetheless, there are concerns about safety regarding segmental thoracic spinal anesthesia and hence is used sporadically. Imbelloni and Gouveia explained the lack of spinal cord injury even during unintentional thoracic dura mater puncture after investigating MR (magnetic resonance) of the thoracic spinal canal in 50 patients. They found that the MR imaging measurements of the distance between the dura mater and spinal cord in the thoracic area were 5.19 mm at T2, 7.75 mm at T5, and 5.88 mm at T10. According to MR imaging, the cord and the cauda equina of the spinal cord are located anteriorly in the thoracic region of the spine and near the dura mater posteriorly in the lumbar region. These anatomical features showed that there is a safe distance at which a needle can be advanced to a point without encountering the cord.⁹

Yousef et al. compared GA, thoracic spinal anesthesia, and lumbar spinal anesthesia for surgery in their study on 90 patients undergoing laparoscopic cholecystectomy who were separated into equal groups. They confirmed that both lumbar and thoracic regional anesthesia are secure alternatives to GA for laparoscopic cholecystectomy in otherwise healthy patients. In comparison to the GA group, the postoperative analgesia was more effective in the regional anesthetic groups. They added that thoracic spinal anesthesia was a better option for daycare surgery since there was a higher level of patient satisfaction there. In comparison to lumbar spinal, segmental thoracic spinal anesthesia

maintains hemodynamic stability with a reduced need for vasopressors and the potential for early ambulation and release.¹⁰

Another concern can be regarding paralysis of respiratory muscles due to the weakening of the thoracic and abdominal muscles that aid in breathing and the blocking of thoracic cardio-acceleratory fibers (T2-T6). A case study of a patient with Byssinosis having a nephrectomy under thoracic spinal anesthesia was published by Kiran and Sweta. They claimed that the use of a small dose of medication administered through injection protects the patient's ability to cough and that the risk of thoracic spinal anesthesia impairing respiration because of larger levels of the block is limited. Since the diaphragm receives its innervation from the cervical level (C3,4,5), its function is unaffected.¹¹

Our patient did not experience dyspnea during abdominal insufflation and SpO₂ was above 96% at all time intervals, perhaps, because of the use of the horizontal position and low gas pressure. She did not experience paresthesia or shoulder tip pain.

Another concern is careful control of the pneumoperitoneal pressure during surgery to ensure adequate diaphragmatic excursion. Because pneumoperitoneum by CO₂ insufflation can stimulate vagal nerve and cause bradycardia, CO₂ must be insufflated slowly, and the maximum intraabdominal pressure should be lowered than 14 mmHg.⁴ In our patient, intraabdominal pressure was maintained at 10 mmHg.

CONCLUSION

Thoracic spinal anesthesia can be considered as an alternative to GA for patients with high risk for GA for laparoscopic cholecystectomy. Patient selection and monitoring of hemodynamic parameters is crucial during the management.

CONSENT

Written informed consent was taken from the patient regarding the case publication.

FINANCIAL SUPPORT

The author(s) did not receive any financial support for the research and/or publication of this article.

CONFLICT OF INTEREST

The author(s) declare that they do not have any conflicts of interest with respect to the research, authorship, and/or publication of this article.

AUTHOR CONTRIBUTIONS

NRB, BN and RS performed literature review. NRB, RS and MKC collected patient data. NRB prepared

the first draft of manuscript. BP, PJ and NRB reviewed and revised the manuscript. All authors contributed to the final version of the manuscript.

REFERENCES

1. Shatri G, Singh A. Thoracic Segmental Spinal Anesthesia. In: StatPearls [Internet]. Treasure Island (FL): StatPearls Publishing; 2023 [cited 2023 Jul 16]. Available from: <http://www.ncbi.nlm.nih.gov/books/NBK572087/>
2. Kejriwal A, Begum S, Krishan G, et al. Laparoscopic cholecystectomy under segmental thoracic spinal anesthesia: A feasible economical alternative. *Anesth Essays Res.* 2017;11(3):781. <https://doi.org/10.4103/0259-1162.174467>
3. Yi JW, Choi SE, Chung JY. Laparoscopic cholecystectomy performed under regional anesthesia in patient who had undergone pneumonectomy - A case report -. *Korean J Anesthesiol.* 2009;56(3):330. <https://doi.org/10.4097/kjae.2009.56.3.330>
4. Nafiu OO, Ramachandran SK, Ackwerh R, et al. Factors associated with and consequences of unplanned post-operative intubation in elderly vascular and general surgery patients: *Eur J Anaesthesiol.* 2011 Mar;28(3):220–4. <https://doi.org/10.1097/EJA.0b013e328342659c>
5. Gupta H, Ramanan B, Gupta PK, et al. Impact of COPD on Postoperative Outcomes. *Chest.* 2013 Jun;143(6):1599–606. <https://doi.org/10.1378/chest.12-1499>
6. Licker MJ, Widikker I, Robert J, et al. Operative Mortality and Respiratory Complications After Lung Resection for Cancer: Impact of Chronic Obstructive Pulmonary Disease and Time Trends. *Ann Thorac Surg.* 2006 May;81(5):1830–7. <https://doi.org/10.1016/j.athoracsur.2005.11.048>
7. Beitler JR, Malhotra A, Thompson BT. Ventilator-induced Lung Injury. *Clin Chest Med.* 2016 Dec;37(4):633–46. <https://doi.org/10.1016/j.ccm.2016.07.004>
8. Imbelloni LE, Sakamoto JW, Viana EP. Segmental Spinal Anesthesia: A Systematic Review. *J Anesth Clin Res.* 2020 Jun 12;
9. Yousef G, Lasheen A, General anesthesia versus segmental thoracic or conventional lumbar spinal anesthesia for patients undergoing laparoscopic cholecystectomy. *Anesth Essays Res.* 2012;6(2):167. <https://doi.org/10.4103/0259-1162.108302>
10. Patel K, Salgaonkar S. Segmental thoracic spinal anesthesia in patient with Byssinosis undergoing nephrectomy. *Anesth Essays Res.* 2012;6(2):236. <https://doi.org/10.4103/0259-1162.108352>