

Management and Early Outcomes of Bile Duct Injuries at University Teaching Hospital

Suyog Bhandari, Pradip Thapa, Deepak Sharma, Narendra Maharjan, Sumita Pradhan, Bishnu Prasad Kandel, Paleswan Joshi Lakhey, Ramesh Singh Bhandari

Author(s) affiliation

Department of Surgical
Gastroenterology, Maharajgunj
Medical Campus, Tribhuvan
University Teaching Hospital,
Institute of Medicine, Kathmandu,
Nepal

Corresponding author

Suyog Bhandari, MBBS, MS
suyogbhandari1@gmail.com

DOI

[10.59779/jiomnepal.1290](https://doi.org/10.59779/jiomnepal.1290)

Submitted

Feb 24, 2024

Accepted

Mar 29, 2024

ABSTRACT

Introduction

Bile duct injury (BDI) management depends upon the type, clinical presentation, available resources and expertise. Some BDI may be managed with endoscopic intervention with Endoscopic Retrograde Cholangio-pancreaticography (ERCP), sphincterotomy and/or stenting while others may require complex surgery and percutaneous interventions by interventional radiologists (IR). This study aimed to evaluate the management strategies and early outcomes of bile duct injuries at Tribhuvan University Teaching Hospital.

Methods

In this retrospective analysis, bile duct injuries in patients treated at Tribhuvan University Teaching Hospital, Kathmandu, Nepal over a period of two years were included (January 2020 to December 2022). In this study we have described the clinical presentation, Strasberg classification of BDI grade, different management techniques and their early outcomes. We calculated number and percentages for categorical variables, mean and standard deviation for continuous data.

Results

Out of 26 bile duct injuries, 12 (46.2%) patients underwent surgical management, 9 (34.6%) underwent percutaneous intervention and 5 (19.2%) underwent endoscopic intervention. Majority of the patient 15 (57.7%) had stricture as an indication for management. Patients who underwent surgical, endoscopic, and percutaneous management showed good early outcomes in 12, 5, and 8 patients respectively. The mean duration of hospital stay was 11.8 ± 5.2 days and CCI was 15.2 ± 9.7 , for patients with index presentation who underwent surgery.

Conclusion

Management of bile duct injuries require multidisciplinary team approach and favorable outcomes can be achieved when managed with expertise at tertiary centers. Surgical management remains essential for complex cases, while percutaneous and endoscopic interventions offer viable alternatives for less severe injuries.

Keywords

Bile duct injuries; Hepp-Couinaud HJ; Redo HJ; stricture

INTRODUCTION

Laparoscopic cholecystectomy (LC) is the preferred method for treating gallstone diseases.¹ With practice of safe cholecystectomy, the incidence of bile duct injury (BDI) is decreasing. However, Bile duct injury, with incidence of 0.3% to 1.4%, is still one of the feared complications of LC resulting in significant morbidity to the patient.²

Around 20% of the injuries to the bile ducts are identified intraoperatively while majority of the biliary injuries are diagnosed postoperatively.^{3,4} Management of BDI is challenging and depends upon the type of BDI, clinical presentation, available resources and expertise. Some BDI may be managed with endoscopic intervention with Endoscopic Retrograde Cholangio-pancreaticography (ERCP), sphincterotomy and/or stenting while other BDI may require complex surgery and percutaneous interventions by interventional radiologists (IR).

Principle of surgical management for BDI is creation of well vascularized, tension free, duct to mucosa biliary-enteric anastomosis, Roux-en-Y Hepaticojejunostomy (HJ) by Hepp-Couinaud technique is the most widely practiced surgery for BDI. Besides early complications, patients are at risk of late complications and impaired quality of life.⁵ Development of biliary-enteric strictures after surgical repair of BDI requires multidisciplinary approach in form of redo HJ or percutaneous drainage and dilatations by IR.

Studies have shown that iatrogenic bile duct injuries treated with a multidisciplinary approach at dedicated hepatobiliary centers result in better outcomes.^{3,4} The purpose of this study was to ascertain the types of bile duct injuries that are treated surgically and nonoperatively, as well as the impact of a multidisciplinary approach on the course of care.

METHODS

The study is a cross-sectional descriptive study and retrospective in nature done at Tribhuvan University Teaching Hospital (TUTH), Institute of Medicine (IOM), Maharajgunj, Kathmandu. We included all the patients with diagnosis of bile duct injury (BDI) or stricture after surgical repair of bile duct injury following LC for gall stone disease from January 2020 to December 2022.

All patients referred with suspected BDI or stricture after repair of bile duct injury were admitted under Department of Surgical Gastroenterology. Patients were evaluated with blood investigations, imaging with Magnetic Resonance Cholangio-Pancreaticography (MRCP) (Figure 1), and tube cholangiogram (Figure 2) when applicable.

The patients were categorized into:

1. Index Presentation: patients presented with BDI without prior management
2. Stricture post HJ for BDI: patients previously managed with Hepaticojejunostomy (HJ) for BDI and presented with HJ stricture

Patients with index presentation were classified according to Strasberg classification.⁶ After thorough evaluation, decision to whether manage by surgical, percutaneous intervention, or endoscopic intervention was based on clinical condition and imaging findings. Surgical management was done with Roux-en-Y HJ by Hepp-Couinaud technique for patients with index presentation. For patients with stricture post HJ for BDI, surgical management was done with Redo Roux-en-Y HJ (Figure 3). Percutaneous interventions were done by team of intervention radiologists (IR) with percutaneous transhepatic biliary drainage (PTBD) and dilatation and stenting of stricture as required. Endoscopic management was done with endoscopic retrograde cholangiopancreatography (ERCP), sphincterotomy and stenting.^{7,8} Early outcomes in terms of

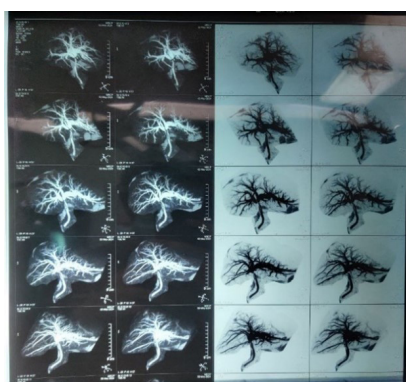

Figure 1. MRCP showing Strasberg E3 BDI

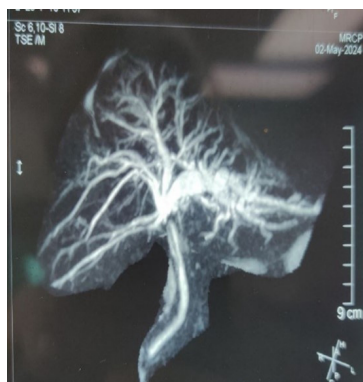

Figure 2. Tube cholangiogram showing Strasberg E3 BDI

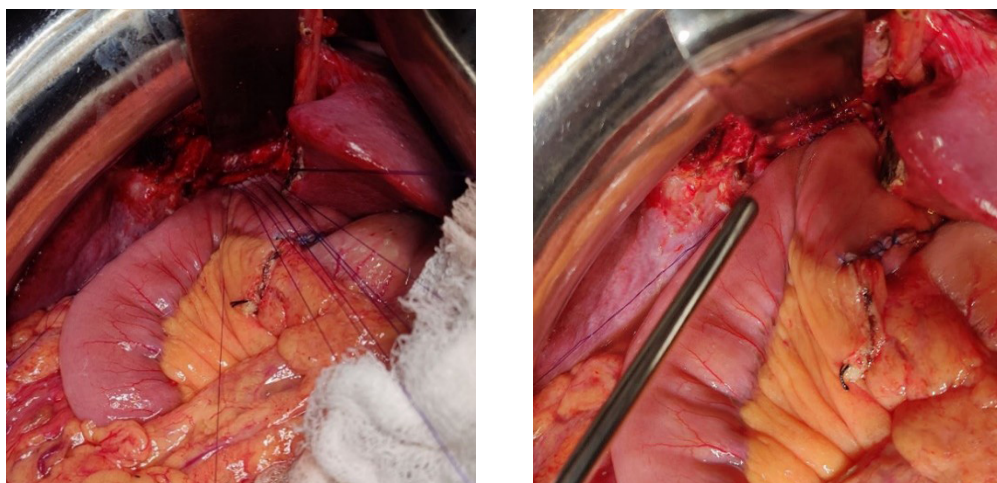


Figure 3. Roux-en-Y HJ by Hepp-Couinaud technique

number of interventions required, grade 3 or more Clavien-Dindo (CD) complications, Comprehensive Complication Index (CCI), duration of hospital stay, were recorded.

This study was ethically approved by the Institutional Review Board of Institute of Medicine. We collected data retrospectively from the patient's records using a structured proforma. We collected the data in Microsoft Excel (Ver. 2016). We used SPSS v 26 (IBM SPSS Statistics for Windows, Version 26.0. Armonk, NY: IBM Corp.) for the statistical analysis. We did descriptive analysis to describe the distribution of socio-demographic characteristics of patients. Number and percentage were calculated for categorical variables while mean and standard deviation (SD) was used for continuous data.

RESULTS

Out of 26 bile duct injuries, 18 (69.2%) patients presented with index presentation and 8 (30.8%) were stricture post HJ for BDI. Among patients with index presentation 8 (44.4%), 5 (27.7%), 5 (27.7%) were managed with surgical intervention, percutaneous intervention, and endoscopic

management respectively. The details of the patient managed by different techniques are shown in Figure 4.

The mean age of the patients was 42.5 ± 2.3 years. Out of 26 patients, male constituted of 30.8% of the patients. The stricture was the most common presentation, 15 (57.7%) patients presented with stricture and 11 (42.3%) presented with bile leaks. Among patients with index presentation after BDI, commonest presentation was Strasberg type A injury, 9 (50%) and 7 (38.8%) patients presented with Strasberg type E (E1-E3) injury. The demographic details of the included patients are shown in Table 1.

The average duration of hospital stay was 11.8 ± 5.2 days among patients who underwent surgery with index presentation. Mean CCI score was 15.2 ± 9.7 in patients managed surgically. One patient (12.5%) had grade 3 or higher complications as defined by Clavien-Dindo. In percutaneous group, median number of interventions was 4 and range 3-6. There was no mortality in patient who were managed for index presentation. The details of early outcomes with index presentation are shown in Table 2.

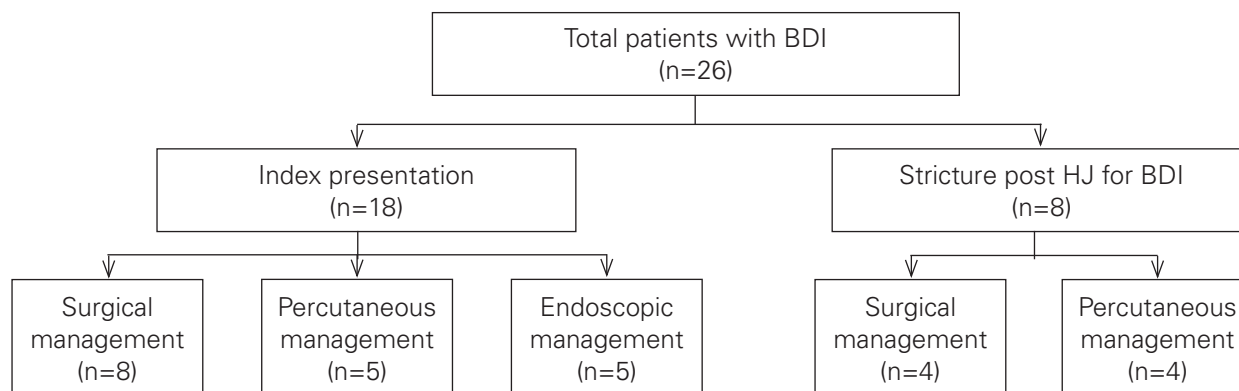


Figure 4. Flowchart of patients with various presentations of BDI and their management

Table 1. Characteristics of patients with BDI (n=26)

Characteristics	Number	Percent
Age in years (Mean \pm SD)	42.5 \pm 2.3	-
Sex		
Male	8	30.8
Female	18	69.2
Comorbidities		
Diabetes	3	11.5
Hypertension	5	19.2
Others	2	7.6
Presentation		
Stricture	15	57.7
Bile leak	11	42.3
Bilirubin (mg/dl) (Mean \pm SD)	2.6 \pm 0.7	-
Type of BDI (Strasberg)		
A	9	34.6
B	1	3.8
C	1	3.8
D	0	-
E1	1	3.8
E2	2	7.6
E3	4	15.3
E4	0	-
Stricture post HJ for BDI	8	30.6

SD: Standard deviation; BDI: Bile Duct Injury; HJ: Hepaticojejunostomy

Eight patients presented with HJ stricture done for BDI at another center. The average duration of hospital stay was 15.8 \pm 6.5 days among patients who underwent redo HJ for stricture post HJ for BDI presentation. Mean CCI score was 20.9 \pm 11.2 in patients managed with redo HJ. Two patients (50%) who underwent surgery had grade 3 or higher complications as defined by Clavien-Dindo in the form of organ space surgical site infection (SSI) and bile leak which were managed with percutaneous drainage. The median number of interventions in percutaneous group was 5 (4-7) with PTBD and dilatations. There was one mortality in patient managed by percutaneous intervention and the patient had presented with secondary biliary cirrhosis with cholangitis. The details of early outcomes with stricture post HJ for BDI presentation are shown in Table 3.

DISCUSSION

This study analyzed the management and early outcomes of 26 patients with BDI or stricture after BDI repair, dividing them into three main treatment groups: surgical management, percutaneous intervention and endoscopic intervention. The most frequent type of injury was bile leak (Strasberg A) in our study, representing 50 % of index cases. Similar findings were reported by Viste A. and Arcerito

Table 2. Early outcomes of patients with index presentation after BDI (n=18)

Variables	Surgical Management (Hepp-Couinaud HJ)	Percutaneous intervention	Endoscopic intervention
Total number of patients	8 (44.4)	5 (27.8)	5 (27.8)
Median number of interventions (Range)	-	4 (3-6)	1
CD Grade \geq 3 complications	1 (12.5)	0	0
CCI (Mean \pm SD)	15.2 \pm 9.7	8.7 \pm 2.3	8.7 \pm 2.3
Mean duration of stay (Mean \pm SD)	11.8 \pm 5.2	9.3 \pm 4.7	9.3 \pm 4.7
Mortality	0	0	0

HJ: Hepaticojejunostomy; SD: Standard Deviation; CD: Clavien-Dindo; CCI: Comprehensive Complication Index

Table 3. Early outcomes of patients presented with stricture post HJ for BDI (n=8)

Variables	Surgical Management (Hepp-Couinaud HJ)	Percutaneous intervention
Total number of patients n(%)	4 (50)	4 (50)
Median number of interventions (Range)	-	5 (4-7)
CD Grade \geq 3 complications n(%)		
Bile leak	1 (25)	1 * (25)
Organ space SSI	1 (25)	
Mortality	0	
CCI	20.9 \pm 11.2	28.7 \pm 2.3
Mean duration of stay	15.8 \pm 6.5	12.2 \pm 3.4

*Presented with secondary biliary cirrhosis with cholangitis

SD: Standard Deviation; CD: Clavien-Dindo; CCI: Comprehensive Complication Index

M., with Strasberg A injuries which accounted for 52.2% and 44.2% of BDIs, respectively.^{9,10} Type A cases were managed using percutaneous or endoscopic interventions.

Regarding management, endoscopic retrograde cholangiopancreatography (ERCP) and sphincterotomy with or without stent placement or with percutaneous drainage can be used to treat minor BDIs, whereas complex BDIs may require surgical intervention with or without endoscopic and percutaneous interventions.

Interventional radiologists play a crucial role in the initial management of bile leaks by placing percutaneous drains if abdominal drain wasn't placed during cholecystectomy or to drain undrained collections. Following these initial measures, a comprehensive assessment of the biliary injury using imaging modalities and more invasive procedures, such as ERCP, percutaneous transhepatic cholangiography (PTC) should be done as required. Incomplete imaging may be associated with poorer surgical outcomes hence, complete cholangiographic characterization of the injury is essential.¹¹ Exploratory laparotomy should be avoided before properly classifying the injury as minor injuries as defined by Strasberg (Strasberg A-D) can often be managed by ERCP, sphincterotomy, or stent placement.^{12,13}

Endoscopic intervention was utilized in 5 (27.8%) patients and was effective for specific injury types (Strasberg type A). Endoscopic treatment for bile duct injuries has a success rate of 66% to 100%, particularly in type A and type D injuries where the injury area is not extensive and biliary continuity is maintained.¹²⁻¹⁵ In our study, there were no complications in this group with success rate of 100%. Sphincterotomy and stenting are the recommended treatments for major biliary leakages. The flow of bile away from the leakage site can be done by; biliary stent placement after ERCP; sphincterotomy, or both. This procedure will reduce the pressure gradient between the duodenum and the injured duct.¹⁶ The most significant late complication of these injuries is stenosis, which develops secondary to biliary leakage.¹⁴

Among patients presented with index presentation, 5 (27.8%) patients were managed with percutaneous interventions. The primary indications for percutaneous intervention were stricture and bile leak. Strasberg type A injuries were the most commonly managed by percutaneous interventions. Type C injury was detected in one of our patients who underwent percutaneous intervention. Type D injury was not detected. Bile duct injuries, which maintain continuity with the rest of the bile ducts, can be treated with percutaneous drainage and endoscopic intervention to reduce intraductal pressure distal to the bile leak.

The mainstay of treatment is surgery in cases of major bile duct injuries. Surgical intervention, specifically Roux-en-Y hepaticojejunostomy (HJ) via the Hepp-Couinaud technique, was the most common method, used in 8 (44.4%) patients with index presentation in our study. The primary indication for surgical intervention included stricture whenever percutaneous dilatation was not feasible. Rafee A. et al. and Stewart. et al. advocate for BDI repair by competent and experienced hepatobiliary surgeons to ensure optimal outcomes.^{17,18} The most common type of injury managed surgically was Strasberg E3 (25%). The principle of treatment for BDI is to restore bilioenteric continuity with well vascularized, tension free, duct to mucosa anastomosis.¹⁹ At our institution, we consistently use Roux-en-Y hepaticojejunostomy via the Hepp-Couinaud technique for repairing major BDIs as this technique has good long-term outcomes, and has lower incidence of postoperative anastomotic strictures.^{12,20} There was bile leak in one patient after Roux-en-Y hepaticojejunostomy with index presentation which is consistent with the literature.²¹

Biliary injury repair is associated with a high failure rate of about 10-19%.^{22,23} In our study, all management strategies demonstrated high rates of improvement, 100% in surgical and endoscopic group and 88.89% in percutaneous intervention group. However, surgically managed patients experienced longer hospital stays (11.8±5.2 days) and higher rates of CD Grade ≥3 complications (12.5%, CCI 15.2±9.7) compared to percutaneous intervention, which had no CD Grade ≥3 complications. Patients who underwent redo HJ for stricture after HJ for BDI had longer duration of hospital stay, CD Grade ≥3 complications and CCI compared to patients with index presentation. Surgical repair remains essential for major BDI requiring anatomical correction, while percutaneous and endoscopic methods provide less invasive options with shorter hospital stays and lower complication rates, suitable for specific injury types and severity levels. In a study of Halbert et al., long-term mortality was 20.8%.²⁴ In our study one mortality was observed among percutaneous intervention group who presented with secondary biliary cirrhosis with cholangitis which was similar in other studies showing mortality rate of 0-3%.^{19,25}

Our study had some limitations. The study design was retrospective and sample size was small. Further, the intraoperative data and post operative long term follow up is lacking. The findings of this study can't be generalized, as the outcomes are based on data from a single center.

CONCLUSION

Management of bile duct injuries require multidisciplinary team approach and favorable outcomes can be achieved when managed with

expertise at tertiary centers. Surgical management remains essential for complex cases, while percutaneous and endoscopic interventions offer viable alternatives for less severe injuries. Prospective studies with larger sample size and longer follow up periods are required to get the long-term results.

FINANCIAL SUPPORT

The author(s) did not receive any financial support for the research and/or publication of this article.

CONFLICT OF INTEREST

The author(s) declare that they do not have any conflicts of interest with respect to the research, authorship, and/or publication of this article.

AUTHOR CONTRIBUTIONS

Study concept and design: SB, BPK, PJL, RSB; Data collection: SB, PT; Analysis and interpretation: SB, DS, NM, SP, RSB; Manuscript draft: SB, RSB All author read approved the final manuscript.

REFERENCES

1. Al-Kubati WR. Bile duct injuries following laparoscopic cholecystectomy: A clinical study. *Saudi J Gastroenterol Off J Saudi Gastroenterol Assoc.* 2010;16(2):100-104. doi:10.4103/1319-3767.61236
2. Abbasoglu O, Tekant Y, Alper A, et al. Prevention and acute management of biliary injuries during laparoscopic cholecystectomy: Expert consensus statement. *Ulus Cerrahi Derg.* 2016;32(4):300-305. doi:10.5152/UCD.2016.3683
3. Machado NO. Biliary complications postlaparoscopic cholecystectomy: mechanism, preventive measures, and approach to management: a review. *Diagn Ther Endosc.* 2011;2011:967017. doi:10.1155/2011/967017
4. Salama IA, Shoreem HA, Saleh SM, et al. Iatrogenic biliary injuries: multidisciplinary management in a major tertiary referral center. *HPB Surg World J Hepatic Pancreat Biliary Surg.* 2014;2014:575136. doi:10.1155/2014/575136
5. Vu HQ, Quach DT, Nguyen BH, et al. Clinical presentation, management and outcomes of bile duct injuries after laparoscopic cholecystectomy: a 15-year single-center experience in Vietnam. *Front Surg.* 2023;10. doi:10.3389/fsurg.2023.1280383
6. Strasberg SM, Hertl M, Soper NJ. An analysis of the problem of biliary injury during laparoscopic cholecystectomy. *J Am Coll Surg.* 1995;180(1):101-125.
7. Dindo D, Demartines N, Clavien PA. Classification of surgical complications: a new proposal with evaluation in a cohort of 6336 patients and results of a survey. *Ann Surg.* 2004;240(2):205-213. doi:10.1097/01.sla.0000133083.54934.ae
8. Clavien PA, Sanabria JR, Strasberg SM. Proposed classification of complications of surgery with examples of utility in cholecystectomy. *Surgery.* 1992;111(5):518-526.
9. Arcerito M, Jamal MM, Nurick HA. Bile Duct Injury Repairs after Laparoscopic Cholecystectomy: A Five-Year Experience in a Highly Specialized Community Hospital. *Am Surg.* 2019;85(10):1150-1154.
10. Viste A, Horn A, Øvrebø K, et al. Bile duct injuries following laparoscopic cholecystectomy. *Scand J Surg SJS Off Organ Finn Surg Soc Scand Surg Soc.* 2015;104(4):233-237. doi:10.1177/1457496915570088
11. Zhu Y, Hickey R. The Role of the Interventional Radiologist in Bile Leak Diagnosis and Management. *Semin Interv Radiol.* 2021;38(3):309-320. doi:10.1055/s-0041-1731369
12. Jabłońska B, Lampe P, Jabłońska B, et al. Reconstructive Biliary Surgery in the Treatment of Iatrogenic Bile Duct Injuries. In: *New Advances in the Basic and Clinical Gastroenterology.* IntechOpen; 2012. doi:10.5772/30733
13. Karvonen J, Gullichsen R, Laine S, et al. Bile duct injuries during laparoscopic cholecystectomy: primary and long-term results from a single institution. *Surg Endosc.* 2007;21(7):1069-1073. doi:10.1007/s00464-007-9316-7
14. Rauws EAJ, Gouma DJ. Endoscopic and surgical management of bile duct injury after laparoscopic cholecystectomy. *Best Pract Res Clin Gastroenterol.* 2004;18(5):829-846. doi:10.1016/j.bpg.2004.05.003
15. Canena J, Horta D, Coimbra J, et al. Outcomes of endoscopic management of primary and refractory postcholecystectomy biliary leaks in a multicentre review of 178 patients. *BMC Gastroenterol.* 2015;15:105. doi:10.1186/s12876-015-0334-y
16. Bridges A, Wilcox CM, Varadarajulu S. Endoscopic management of traumatic bile leaks. *Gastrointest Endosc.* 2007;65(7):1081-1085. doi:10.1016/j.gie.2006.11.038
17. AbdelRafee A, El-Shobari M, Askar W, et al. Long-term follow-up of 120 patients after hepaticojunostomy for treatment of post-cholecystectomy bile duct injuries: A retrospective cohort study. *Int J Surg Lond Engl.* 2015;18:205-210. doi:10.1016/j.ijssu.2015.05.004
18. L S, Lw W. Laparoscopic bile duct injuries: timing of surgical repair does not influence success rate. A multivariate analysis of factors influencing surgical outcomes. *HPB.* 2009;11(6). doi:10.1111/j.1477-2574.2009.00096.x
19. Çavuşoğlu SD, Doğanay M, Birben B, et al. Management of Bile Duct Injuries: A 6-year Experience in a High Volume Referral Center. *Euroasian J Hepato-Gastroenterol.* 2020;10(1):22-26. doi:10.5005/jp-journals-10018-1309
20. Mercado MA, Domínguez I. Classification and management of bile duct injuries. *World J Gastrointest Surg.* 2011;3(4):43-48. doi:10.4240/wjgs.v3.i4.43
21. Hajjar NA, Tomuş C, Mocan L, et al. Management of bile duct injuries following laparoscopic cholecystectomy: long-term outcome and risk factors influencing biliary reconstruction. *Chir Buchar Rom.* 2014;109(4):493-499.
22. Sikora SS, Pottakkat B, Srikanth G, et al. Postcholecystectomy Benign Biliary Strictures – Long-Term Results. *Dig Surg.* 2006;23(5-6):304-312. doi:10.1159/000097894
23. Schmidt SC, Langrehr JM, Hintze RE, et al. Long-term results and risk factors influencing outcome of major bile duct injuries following cholecystectomy. *Br J Surg.* 2004;92(1):76-82. doi:10.1002/bjs.4775
24. Halbert C, Altieri MS, Yang J, et al. Long-term outcomes of patients with common bile duct injury following laparoscopic cholecystectomy. *Surg Endosc.* 2016;30(10):4294-4299. doi:10.1007/s00464-016-4745-9
25. Barrett M, Asbun HJ, Chien HL, et al. Bile duct injury and morbidity following cholecystectomy: a need for improvement. *Surg Endosc.* 2018;32(4):1683-1688. doi:10.1007/s00464-017-5847-8