

## Case Report

## Unusual neurological cause of intractable hiccups: A case report

Thapa B<sup>1</sup>, Sedain G<sup>2</sup>, Sharma MR<sup>2</sup><sup>1</sup> Department of General Surgery, <sup>2</sup>Department of Neurosurgery, Maharajgunj Medical Campus, Tribhuvan University Teaching Hospital, Kathmandu

Correspondence to: Dr. Bikas Thapa

Email: bikasthapa1141@gmail.com

## Abstract

Intractable hiccups is a poorly understood medical problem and the pathophysiology is highly debatable. Here we report a interesting case of 40 year male patient who presented to us with complains of difficulty in swallowing and hiccups for 3 weeks which was resistant to medication . MRI scans revealed Chiari I malformation and cervical syrinx. He underwent Suboccipital craniectomy including a C1 laminectomy following which he was relieved of intractable hiccups.

## Introduction

Intractable hiccups is a poorly understood medical problem and the pathophysiology is highly debatable. Hiccups consist of brief bursts of intense inspiratory activity involving the diaphragm and the inspiratory intercostal muscles, with reciprocal inhibition of expiratory intercostals muscles, the sound and discomfort resulting from glottis closure immediately after the onset of diaphragmatic contraction.<sup>1</sup> Most episodes of hiccups are self-limited, but prolonged or intractable hiccups should prompt a search for a cause. Hiccups are defined as intractable when they persist for 24 hours. The afferent pathway of the hiccup reflex arc includes the sensory branches of the phrenic and vagus nerves and dorsal sympathetic fibers; the main efferent limb, causing spasm of the diaphragm, is composed of motor fibers of the phrenic nerve.<sup>2</sup>

## Case report

A 40 year male patient presented to us with complains of difficulty in swallowing and hiccups for 3 weeks. His hiccups were refractory to baclofen, metoclopramide and chlorpromazine. Blood urea was normal and evaluation by other departments couldnot reveal any cause. Neurological examination revealed hyperreflexia of all 4 limbs and suspended sensory loss in the upper extremities. Cranial nerve examination demonstrated no positive neurological findings, including

bilateral gag reflexes, except for the persisting hiccups. Preoperative magnetic resonance imaging (MRI) scans revealed Chiari I malformation and cervical syrinx.

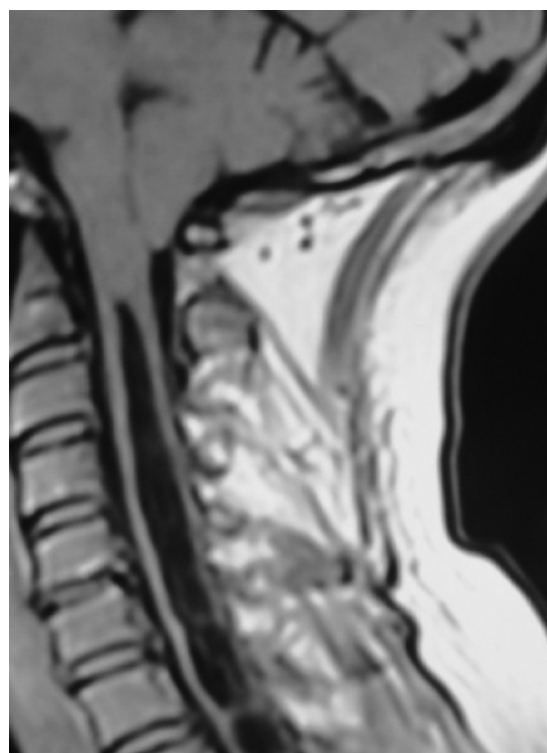


Figure 1. MRI showing chiari I with syrinx

Suboccipital craniectomy including a C1 laminectomy was performed. Dura was opened in Y shaped fashion, subpial tonsillar resection and duraplasty was done. Post operative course was uneventful.

Hiccups disappeared for 2 days post op but reappeared again with decreased frequency and finally after 2 weeks patient was relieved of the vexing problem.

## Discussion

Although their pathophysiological cause remains unclear, hiccups or singultus are thought to be related to stimulation, probably by damage or irritation, of one or more points of the hiccup reflex arc. The hiccup reflex arc includes an afferent portion that involves the vagus nerve, the phrenic nerve, and the sympathetic chain arising from T6–T12. The hiccup centers are thought to be located either in the brainstem close to the inspiratory centers or in the cervical cord between C3 and C5.<sup>3</sup> The efferent limb consists primarily of the phrenic nerve and its interactions with the glottis and accessory respiratory muscles, and the complex interactions between the brainstem and midbrain areas, including the dorsal portion of the nucleus tractus solitarius (inspiratory center), the ventral group of the nucleus ambiguus (expiratory center), phrenic nerve nuclei, medullary reticular formation, and hypothalamus.<sup>4</sup>

Intractable hiccups as a presenting symptom of cerebellar hemangioblastoma<sup>5</sup> medulla oblongata cavernoma<sup>6</sup>, and rare cases of medullary compressive lesions presenting with intractable hiccups<sup>7</sup> have been reported. Fisher et al.<sup>8</sup> reported dorsal and lateral medullary infarctions presenting with persistent hiccup. Kumral and Acarer<sup>9</sup> described an unusual case of primary medullary haemorrhage with intractable hiccup. There have been some reports describing cases of intractable hiccups associated with extensive syringomyelia and Chiari malformation.<sup>10,11</sup>

Because compression of the medulla oblongata by the herniated tonsil is a common finding in syringomyelia associated with Chiari malformations. It is likely that medullary compression played a role in pathogenesis in our patient. It is often difficult to treat intractable hiccups. Baclofen, haloperidol, carbamazepine, and chlorpromazine have been recommended for the treatment of intractable hiccups<sup>2</sup>. Electrical stimulation of the phrenic or vagus nerves and microvascular decompression of the vagus nerve have been reported for the treatment of hiccups<sup>12,13,14</sup>. In our case, intractable hiccups associated with syringomyelia was successfully treated with foramen magnum decompression. When persistent intractable hiccups occur, with or without slow neurological deterioration, intracranial lesion should be suspected. MRI scans obtained at the time of the initial diagnosis and at follow-up assessments are valuable. Hiccups caused by syringomyelia and Chiari

malformations represent a surgically treatable disorder, although the incidence is low.

**Conflict of Interest:** None declared

## References

1. Larner AJ (2006) Hiccup. In: Larner AJ (ed) A dictionary of neurological signs. Second edition edn. Springer, UK, p 153
2. Fodstad H, Nilsson S. Intractable singultus: a diagnostic and therapeutic challenge. *Br J Neurosurg* 1993; 7:255–62
3. Salem MR, Baraka A, Rattenborg CC, Holaday DA: Treatment of hiccups by pharyngeal stimulation in anesthetized and conscious subjects. *JAMA* 202:126–130, 1967
4. Howard RS (1992) Persistent hiccups. *BMJ* 305:1237–1238
5. Nagayama T, Kaji M, Hirano H, Niino M, Kuratsu J (2004) Intractable hiccups as a presenting symptom of cerebellar hemangioblastoma. *J Neurosurg* 100:1107–1110
6. Musumeci A, Cristofori L, Bricolo A (2000) Persistent hiccup as presenting symptom in medulla oblongata cavernoma: a case report and review of the literature. *Clin Neurol Neurosurg* 102:13–17
7. Amirjamshidi A, Abbassioun K, Parsa K (2007) Hiccup and neurosurgeons: a report of 4 rare dorsal medullary compressive Pathologies and review of the literature. *Surg Neurol.* 67: 395–402
8. Fisher CM, Karnes WE, Kubik CS. Lateral medullary infarction. The pattern of vascular occlusion. *J Neuropath Exp Neurol* 1961; 20:323–79
9. Kumral E, Acarer A. Primary medullary haemorrhage with intractable hiccup. *J Neurol* 1998; 245(9):620–2.
10. Vanamoorthy P, Kar P, Prabhakar H. Intractable hiccups as a presenting symptom of Chiari I malformation. *Acta Neurochir* (2008) 150:1207–1208
11. Loft LM, Ward RF: Hiccups: A case presentation and etiologic review. *Arch Otolaryngol Head Neck Surg* 118:1115–1119, 1992
12. Aravot DJ, Wright G, Rees A, Maiwand OM, Garland MH: Non-invasive phrenic nerve stimulation for intractable hiccups. *Lancet* 2:1047, 1989 (letter).
13. Johnson DL: Intractable hiccups: Treatment by microvascular decompression of the vagus nerve. *J Neurosurg* 78:813–816
14. Oshima T, Sakamoto M, Tatsuta H, Arita H: GABAergic inhibition of hiccup-like reflex induced by electrical stimulation in medulla of cats. *Neurosci Res* 30:287–293, 1998.